

PATIENT PRESENTING CLINICAL SIGNS

Norman Cat Posse Norman was presented for evaluation of edema in the left rear limb/ non weight bearing for the past 3 days.

SPECIES RADIOGRAPHIC STUDY OF THE TARSI

Canine Mediolateral and dorsoplantar view of the bilateral tarsi available for review. There are also mediolateral views of the stifles. However, interpretation of the tarsi region only requested.

BREED RADIOGRAPHIC FINDINGS

DSH Moderate soft tissue swelling is seen in the region of the left achilles tendon as well as plantar and distal to the left tuber calcis. Mild generalized soft tissue swelling in the periarticular soft tissues circumferential to the left tarsus and left metatarsus is seen as well. There is no evidence of articular involvement. No osseous abnormalities of the left tarsus or metatarsus.

SEX

Neutered Male The right tarsus presents within normal age related limits.

RADIOGRAPHIC DIAGNOSIS

- Soft tissue swelling of the left achilles tendon with diffuse swelling in the left tarsal and metatarsal regions.

AGE

6 Years

INTERPRETATION OF FINDINGS & FURTHER RECOMMENDATIONS

INTERPRETED BY

Nele Eley (Ondreka),
DVM Dr. med. vet.,
DipECVDI

The radiographic findings suggest potential for injury of the left achilles tendon. Swelling of the distal part of the tendon with loss of the regular tendon layering is seen, and tendonitis as well as rupture/partial rupture could be considered. The diffuse peripheral swelling is likely to represent edema, hematoma, or cellulitis.

HOSPITAL NAME

DTLA Vets

REFERRING VET

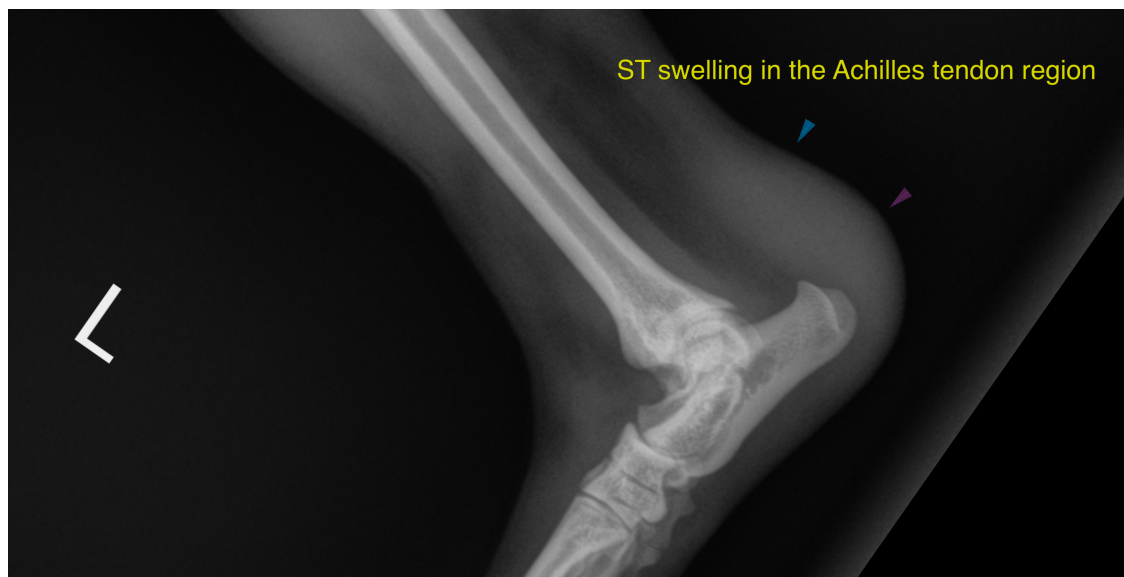
Dr. Montoya

INVOICE

46955

DATE

4/26/23





PATIENT

The information and recommendations provided are based on the images presented by the referring veterinarian. No evaluation can be communicated regarding pathology that was not visible in the image/video clips provided.

Norman Cat Posse

SPECIES

Thank you for this referral. If the clinical or image interpretation does not parallel your findings or if I can be of any further assistance please contact me.

Canine

BREED

Nele Eley (Ondreka), DVM, Dr. med. vet., DipECVDI
European Specialist in Veterinary Diagnostic Imaging, Cert. Radiology,
Senior lecturer University of Giessen/Germany, Veterinary Faculty, Department of Radiology.
Nele.Eley@sonopath.com

DSH

SEX

Neutered Male

AGE

6 Years

INTERPRETED BY

Nele Eley (Ondreka),
DVM Dr. med. vet.,
DipECVDI

HOSPITAL NAME

DTLA Vets

REFERRING VET

Dr. Montoya

INVOICE

46955

DATE

4/26/23