



**PATIENT PRESENTING CLINICAL SIGNS**

Abby Harvey  
 Abby was examined through TSVS for a complaint of left hind lameness. She has had a wedge trochleoplasty and tibial tuberosity transposition surgery done in 2019 to address medial patella luxation on the same limb. She also had a TPLO performed on the right hind to address cranial cruciate disease in 2021. P presented on 2/7/23- Guarding left front limb. Post op TPLO left on leg that had a previous MPL repair. Swelling and crepitance left stifle. Painful with decreased ROM. Stiff on extension of left front. Medial buttress right stifle with crepitance. Head bob on walk. Grade II lameness left rear on walk. Bunny hop in rear limbs on trot. Weakness on left rear. Muscle atrophy left thigh muscles and mild in right. P presented on 4/20/23- Still minimal weight bearing on hind leg. Had rads done yesterday and is seeing Dr. Israel soon. Crepitance present in stifle.

Canine

Pitbull Mix

Abnormal PE/Chem/CBC/UA Results: Thyroid value was normal, no other BW.

**ULTRASONOGRAPHIC FINDINGS**

Spayed Female  
 The right stifle has a history of cruciate ligament injury and TPLO. The left stifle has a history of medial patella luxation, trochleoplasty, and tibial tuberosity transposition.

**Right Stifle**

Moderate swelling of the right stifle joint's synovium, mild capsular fibrosis, and moderate periarticular osteophytes are seen. There is a mild amount of anechoic effusion within the suprapatellar recess of the right stifle joint. The patella tendon presents thin and smooth and within normal limits. No evidence of post-TPLO desmopathy is seen. A small patella enthesophyte is noted. The infrapatellar fat pad is uniform in echotexture. The cruciate ligament presents as a short, smooth, echogenic stump at the intercondylar eminence of the tibia. The medial meniscus is not included in this study.

**Left Stifle**

Mild effusion, moderate synovial swelling, and moderate osteophytosis are seen in the femoral patella compartment. The patella tendon presents thin and smooth. A small patella tendon enthesophyte is seen. The infrapatellar fat is uniform in echotexture. The cruciate ligament is not entirely visible. No direct abnormality of the cranial cruciate ligament is noted, and the medial meniscus is not included in the study.

**ULTRASONOGRAPHIC DIAGNOSIS**

- History of right cruciate ligament injury and TPLO with moderate osteoarthritis.
- History of left medial patella luxation and trochleoplasty as well as transposition of the tibial tuberosity with mild to moderate osteoarthritis accentuating the femoral patella compartment – no overt cruciate ligament injury is seen.

**INTERPRETATION OF THE FINDINGS & FURTHER RECOMMENDATIONS**

The ultrasonographic findings are within expected limits considering the history of cruciate ligament injury and TPLO of the right stifle as well as medial patella luxation with trochleoplasty and tibial tuberosity transposition of the left stifle. The medial meniscus is not seen in this study. However, most patients with medial meniscal injury present a higher degree of effusion and synovialitis compared to this case. Clinical correlation is required.

**INTERPRETED BY**

Nele Eley, DVM  
 Dr. med. Vet. DipECVDI

**HOSPITAL NAME**

County Line  
 Veterinary Clinic

**REFERRING VET**

Elizabeth Fowler

**INVOICE**

58002

**DATE**

4-26-23



**PATIENT**

Abby Harvey

**SPECIES**

Canine

**BREED**

Pitbull Mix

**SEX**

Spayed Female

**AGE**

7/1/2017

**INTERPRETED BY**

Nele Eley, DVM  
Dr. med. Vet. DipECVDI

**HOSPITAL NAME**

County Line  
Veterinary Clinic

**REFERRING VET**

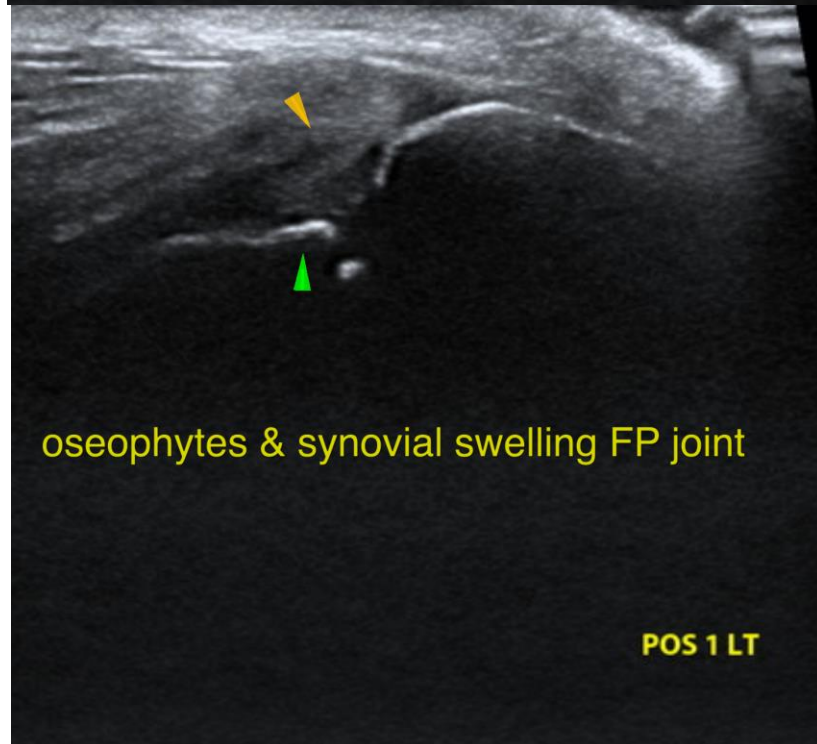
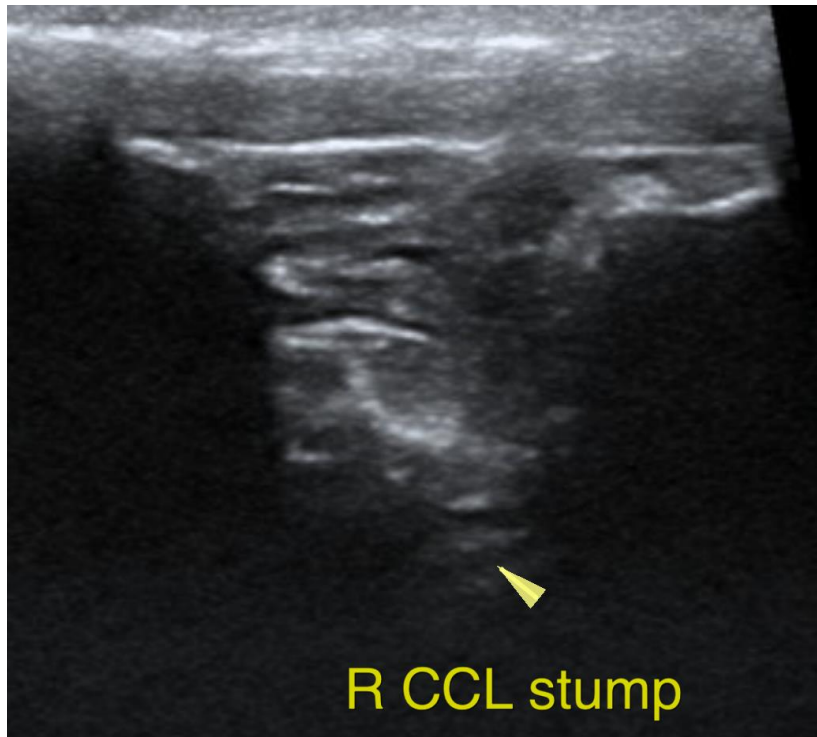
Elizabeth Fowler

**INVOICE**

58002

**DATE**

4-26-23





**PATIENT**

Abby Harvey

The information and recommendations provided are based on the images presented by the referring veterinarian/sonographer. No evaluation can be communicated regarding pathology that was not visible in the image/video clips provided.

Thank you for this referral. If the clinical or image interpretation does not parallel your findings or if I can be of any further assistance please contact me.

**SPECIES**

Canine

**Nele Eley**, DVM, Dr. med. vet., DipECVDI  
European Specialist in Veterinary Diagnostic Imaging, Cert. Radiology,  
Senior lecturer University of Giessen, Germany, Veterinary Faculty, Department of Radiology  
Nele.Eley@sonopath.com

**BREED**

Pitbull Mix

**SEX**

Spayed Female

**AGE**

7/1/2017

**INTERPRETED BY**

Nele Eley, DVM  
Dr. med. Vet. DipECVDI

**HOSPITAL NAME**

County Line  
Veterinary Clinic

**REFERRING VET**

Elizabeth Fowler

**INVOICE**

58002

**DATE**

4-26-23