



PATIENT

Abby Frankel

PRESENTING CLINICAL SIGNS

right laryngeal weakness and left paralysis and elongated soft palate.
Abnormal PE/Chem/CBC/UA Results: creatinine on 3-24-23. History of mild neutrophilic leukocytosis on 3-24-23

SPECIES

Canine

COMPUTED TOMOGRAPHIC STUDY OF THE HEAD, NECK, & THORAX

Plain studies available for review.

BREED

Westie

COMPUTED TOMOGRAPHIC FINDINGS

Head & Neck

Severe periodontal space widening is seen circumferential to the roots of the triadan 109 with regional peripheral soft tissue swelling.

SEX

Female

Mild generalized swelling of the laryngeal soft tissues is seen. A mild amount of residual air is seen in the laryngeal ventricles.

AGE

9 Years

Mild redundancy of the dorsal tracheal ligament of the cervical trachea is noted.

Both lobes of the thyroid gland are seen and present within normal limits.

Thorax

The intrathoracic trachea presents within normal limits.

The degree of pulmonary inflation appears adequate. Mild peripheral ventral atelectatic changes are seen. There is a mild diffuse increase in interstitial attenuation and mild generalized bronchial wall enhancement.

The mediastinal lymph nodes present within normal limits.

No obvious cardiovascular pathology is seen.

The thoracic boundaries present within normal limits.

A mild amount of gas is seen in the esophagus.

COMPUTED TOMOGRAPHIC DIAGNOSIS

- Tooth root abscessation triadan 109.
- Mild laryngeal soft tissue swelling
- Redundant dorsal tracheal ligament.
- Normal age related thorax with atelectatic changes of the lung.

INVOICE

58181

DATE

4-26-23

INTERPRETATION OF THE FINDINGS & FURTHER RECOMMENDATIONS

Note the presence of tooth root abscessation with peripheral cellulitis of the triadan 109. Dental extraction and generalized dental revision should be considered.

INTERPRETED BY

Nele Eley, DVM
Dr. med. Vet. DipECVDI

HOSPITAL NAME

Animal Surgical
Center

REFERRING VET

Dr. Puccio



PATIENT

Abby Frankel

The laryngeal soft tissue swelling may represent edema or inflammation such as laryngitis. Correlation with the endoscopic workup recommended.

SPECIES

Canine

Redundancy of the dorsal tracheal ligament can be an incidental finding. It can however be associated with dynamic tracheal disease.

BREED

Westie

The mild bronchial wall enhancement can be within age related normal limits. Low grade lower airway disease such as allergic/eosinophilic bronchopneumopathy or bronchitis cannot be ruled out entirely.

SEX

Female

AGE

9 Years

INTERPRETED BY

Nele Eley, DVM
Dr. med. Vet. DipECVDI

HOSPITAL NAME

Animal Surgical
Center

REFERRING VET

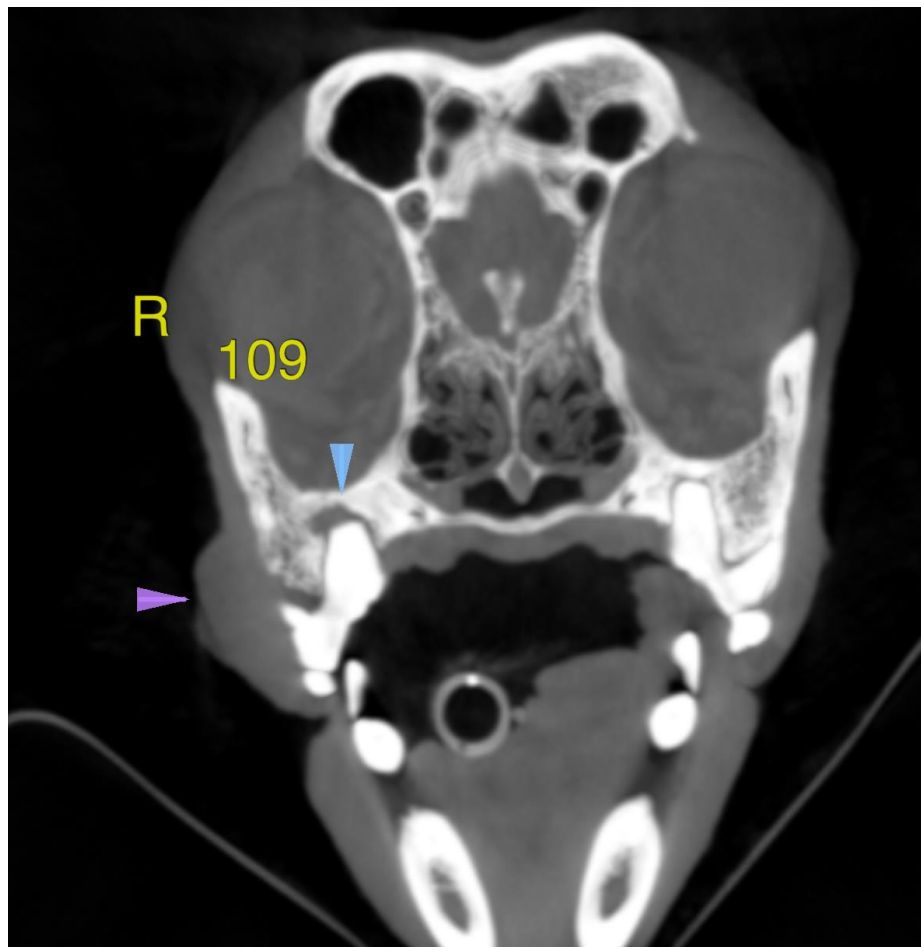
Dr. Puccio

INVOICE

58181

DATE

4-26-23





PATIENT

Abby Frankel

The information and recommendations provided are based on the images presented by the referring veterinarian/sonographer. No evaluation can be communicated regarding pathology that was not visible in the image/video clips provided.

Thank you for this referral. If the clinical or image interpretation does not parallel your findings or if I can be of any further assistance please contact me.

SPECIES

Canine

Nele Eley, DVM, Dr. med. vet., DipECVDI
European Specialist in Veterinary Diagnostic Imaging, Cert. Radiology,
Senior lecturer University of Giessen, Germany, Veterinary Faculty, Department of Radiology
Nele.Eley@sonopath.com

BREED

Westie

SEX

Female

AGE

9 Years

INTERPRETED BY

Nele Eley, DVM
Dr. med. Vet. DipECVDI

HOSPITAL NAME

Animal Surgical
Center

REFERRING VET

Dr. Puccio

INVOICE

58181

DATE

4-26-23