


PATIENT PRESENTING CLINICAL SIGNS

Perdido Zachary Abdominal respiration No heart murmur Weight Loss
 Abnormal PE/Chem/CBC/UA Results: Pending labwork

SPECIES RADIOGRAPHIC STUDY OF THE THORAX & ABDOMEN

Feline Right and left lateral views of the thorax and abdomen totaling 3 images.

RADIOGRAPHIC FINDINGS

BREED Patient's body condition score appears to be excessive.

DSH Mild generalized osteopenia is noted. Severe L6/7 and L7/S1 spondyloses are present.

SEX An approximately 5.0 cm sized soft tissue opaque mass is seen in the cranioventral abdomen and border effacing with the liver. Caudal deviation of the stomach is noted.

Neutered Male One of the kidneys appears to be enlarged. The contralateral kidney appears relatively small in size.

AGE A bates body is seen in the caudal abdomen, dorsal to the descending colon.

18 Years There is a moderate amount of pleural effusion.

The lung lobe margins are retracted from the thoracic wall and rounded. No evidence of pulmonary masses.

INTERPRETED BY

Nele Eley (Ondreka),
 DVM Dr. med. vet.,
 DipECVDI

The trachea is mildly elevated.

The cardiac silhouette appears to be enlarged, even though its visibility is partially obscured due to the presence of the pleural fluid.

Enlargement of the cranial lobar pulmonary vessels is suspected.

HOSPITAL NAME

New Bridge VP

RADIOGRAPHIC DIAGNOSIS
REFERRING VET

Dr. Abina Glennon

- Moderate bilateral pleural effusion – suspect cardiomegaly.
- Cranial abdominal soft tissue mass border effacing with the liver.
- Suspect reduced size of one kidney and enlargement of the other.
- Generalized osteopenia, likely age related
- Degenerative lumbosacral stenosis, unrelated to the reason for clinical presentation

INVOICE INTERPRETATION OF FINDINGS & FURTHER RECOMMENDATIONS

46930 The radiographic study reveals pleural effusion. Differential diagnosis includes transudate, modified transudate, exudate, and chylous effusion. Further definition would require aspiration and analysis of the pleural fluid. A cardiac echo should be considered owing to the impression of concurrent cardiomegaly to rule out congestive cardiac failure as underlying cause of the effusion.

DATE

4/25/23



PATIENT Perdido Zachary
 A large soft tissue mass is present within the cranial abdomen. Hepatic origin is by far most likely. Splenic, lymph node, or other origin cannot be ruled out entirely. Differential diagnosis includes neoplasia as well as granuloma, abscess, hematoma. Further definition by means of abdominal ultrasound could be considered.

SPECIES Feline
 The most likely cause of the difference in renal size is chronic renal disease with fibrosis and end stage renal disease of one and compensatory hyperplasia of the contralateral kidney. However, neoplasia, nephritis, perirenal cysts and other cannot be ruled out entirely. Consider abdominal ultrasound to further define.

BREED

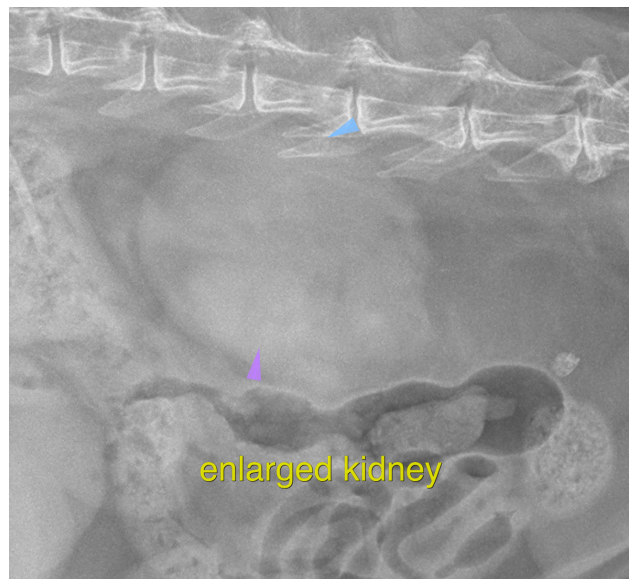
DSH

SEX

Neutered Male

AGE

18 Years



INTERPRETED BY

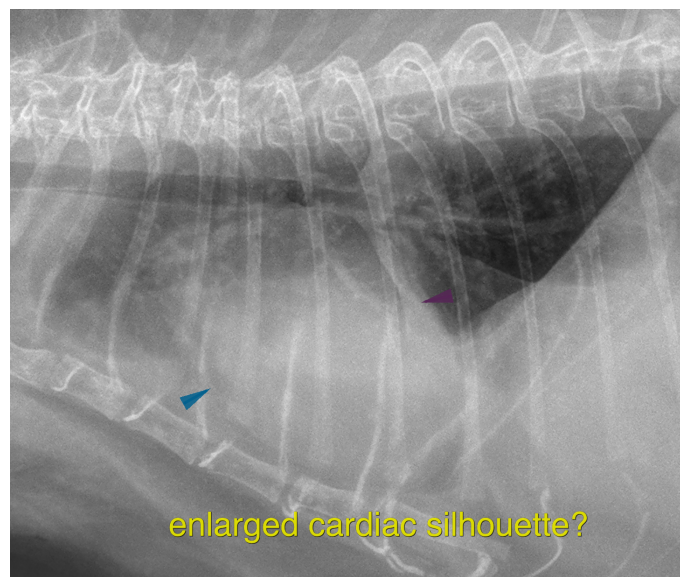
Nele Eley (Ondreka),
 DVM Dr. med. vet.,
 DipECVDI

HOSPITAL NAME

New Bridge VP

REFERRING VET

Dr. Abina Glennon

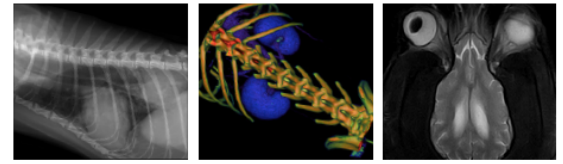


INVOICE

46930

DATE

4/25/23



PATIENT

Perdido Zachary

SPECIES

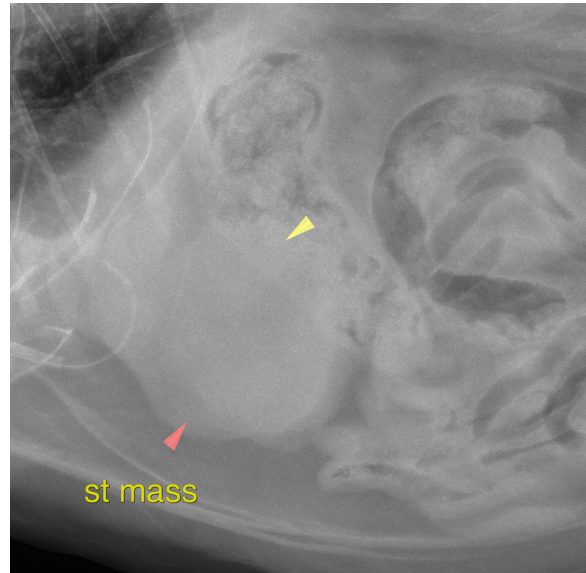
Feline

BREED

DSH

SEX

Neutered Male



AGE

18 Years

The information and recommendations provided are based on the images presented by the referring veterinarian. No evaluation can be communicated regarding pathology that was not visible in the image/video clips provided.

Thank you for this referral. If the clinical or image interpretation does not parallel your findings or if I can be of any further assistance please contact me.

INTERPRETED BY

Nele Eley (Ondreka),
DVM Dr. med. vet.,
DipECVDI

Nele Eley (Ondreka), DVM, Dr. med. vet., DipECVDI
European Specialist in Veterinary Diagnostic Imaging, Cert. Radiology,
Senior lecturer University of Giessen/Germany, Veterinary Faculty, Department of Radiology.
Nele.Eley@sonopath.com

HOSPITAL NAME

New Bridge VP

REFERRING VET

Dr. Abina Glennon

INVOICE

46930

DATE

4/25/23