



PATIENT PRESENTING CLINICAL SIGNS

Roxie Balaban 9YR OLD SPAYED PITBULL PRESENTED TODAY FOR ACUTE VOMITING. pET WAS FINE YESTERDAY AM BUT WHEN OWNER RETURNED AT 7PM FROM WORK SHE HAD SOME DIARRHEA. SHE ATE LAST NIGHT BUT NOT INTERESTED THIS AM. SHE IS DRINKING A LOT BUT VOMITING SHORTLY AFTER. PET IS STILL BAR!!

SPECIES

Canine

BREED

Pitbull Mix

Abnormal PE/Chem/CBC/UA Results: Physical Examination Key -- (N= Normal, A= Abnormal)
 CV/Respiratory: Normal heart rate and rhythm, no murmur, pulses strong and synchronous, normal bronchovesicular sounds. EENT: Clear OU and AU. No nasal discharge. No cough on tracheal palpation. Oral cavity: mild dental tartar Musculoskeletal: BCS = 7/9. Ambulatory x 4
 Uro/Perineum: No significant lesions Abd/GI: Soft, non-painful. No masses or fluid wave palpated
 Lymph Nodes: No peripheral lymphadenopathy Neurological: Alert and appropriate. No significant abnormalities Skin: Good hair coat. No ectoparasites seen Mentation: BAR Hydration: ~5% dehydration Rectal: No masses, soft stool, no bleeding

SEX

SF

RADIOGRAPHIC STUDY OF THE ABDOMEN

The patient is obese.

Multiple spondyloses are seen throughout the thoracolumbar spine.

AGE

9 Years, 5 Months

The stomach is empty.

The small intestinal loops are evenly distributed throughout the mid abdomen. No obvious abnormal dilation or plication is seen. A segment of the small intestine appears to be lined with mineral opaque material.

INTERPRETED BY

Nele Eley, DVM
 Dr. med. Vet. DipECVDI

The descending colon contains a moderate amount of gas and fluid.

RADIOGRAPHIC DIAGNOSIS

- Mineral opaque small intestinal content.
- Gastrointestinal maldigestion pattern.

HOSPITAL NAME

DPC Veterinary Hospital

INTERPRETATION OF THE FINDINGS & FURTHER RECOMMENDATIONS

The mineral opaque material lining a segment of the small intestine may represent positive contrast media, however, small intestinal foreign material including sand and other should be considered should the patient not have been administered positive contrast media at some point prior to taking these radiographs. Otherwise, abdominal ultrasound would be ideal for further definition. A radiographic recheck could be considered should ultrasound not be available.

REFERRING VET

Dr. Rivera

INVOICE

51738

DATE

4-25-22



PATIENT

Roxie Balaban

SPECIES

Canine

BREED

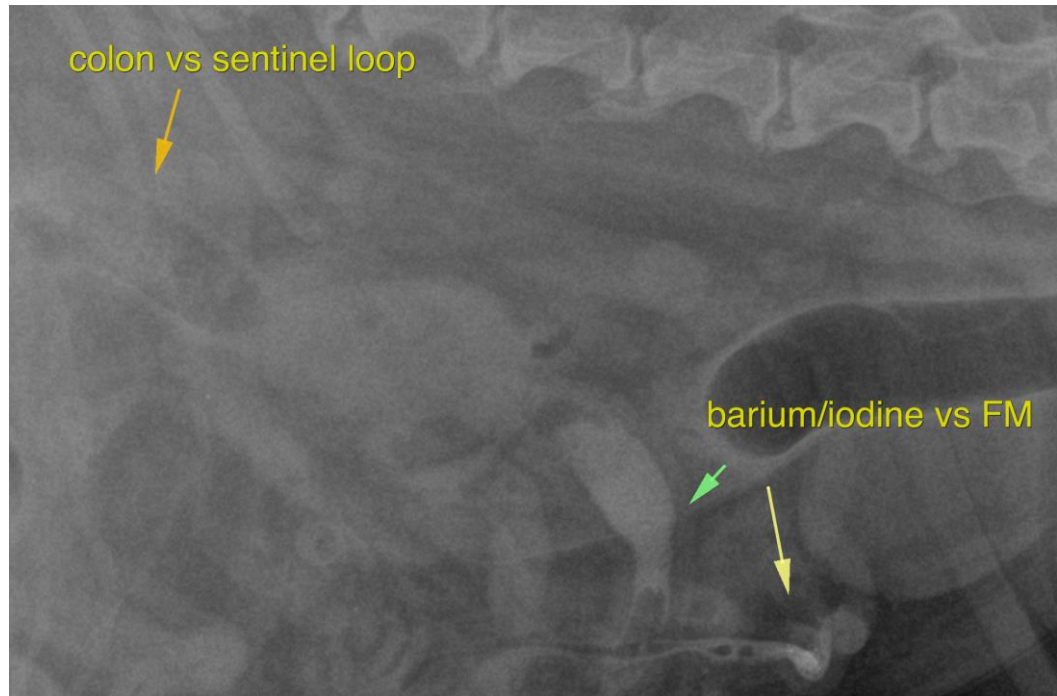
Pitbull Mix

SEX

SF

AGE

9 Years, 5 Months



INTERPRETED BY

Nele Eley, DVM
Dr. med. Vet. DipECVDI

The information and recommendations provided are based on the images presented by the referring veterinarian/sonographer. No evaluation can be communicated regarding pathology that was not visible in the image/video clips provided.

HOSPITAL NAME

DPC Veterinary
Hospital

Thank you for this referral. If the clinical or image interpretation does not parallel your findings or if I can be of any further assistance please contact me.

Nele Eley, DVM, Dr. med. vet., DipECVDI
European Specialist in Veterinary Diagnostic Imaging, Cert. Radiology,
Senior lecturer University of Giessen, Germany, Veterinary Faculty, Department of Radiology
Nele.Eley@sonopath.com

REFERRING VET

Dr. Rivera

INVOICE

51738

DATE

4-25-22