



PATIENT

Toby Porter

PRESENTING CLINICAL SIGNS

Limping on the L hind. It happened on Friday. Thought a horse stepped on him. He is a crazy boy and runs around a lot. Didn't eat this morning.

SPECIES

Canine

Abnormal PE/Chem/CBC/UA Results: left hind 4/5 lame. All normal save left stifle: medial buttress, effusion, meniscal click, and cranial drawer. Stage i dental disease severe base narrow canine with divets dug into the palate by 304 and 404.

BREED

Blue Heeler

RADIOGRAPHIC STUDY OF THE STIFLES & PELVIS

Mediolateral and craniocaudal views of both stifles and ventrodorsal and lateral views of the pelvis totaling 7 images available for review.

RADIOGRAPHIC FINDINGS

SEX

Male

Pelvis

The muscle volume of the hind limbs appears to be symmetric and adequate.

The coxofemoral joints present within normal limits.

AGE

1 Year, 8 Months

Both femoral heads are round and deeply situated within the acetabulum. The joint spaces are narrow and even.

No evidence of osteoarthritic changes is seen.

INTERPRETED BY

Nele Eley, DVM
Dr. med. Vet. DipECVDI

There is no evidence of traumatic osseous or articular injury.

Stifles

HOSPITAL NAME

Elizabeth Animal
Hospital

There appears to be mild increase in articular swelling and mild cranial thrust of the tibia in the left stifle comparing the left and right hind limb.

The assessment of the soft tissues, however, is limited due to detector oversaturation.

The popliteal sesamoid bone is slightly further distal in the left stifle compared with the right side.

REFERRING VET

Leon Anderson, DVM

The right stifle joint presents within normal limits.

RADIOGRAPHIC DIAGNOSIS

- Suspect articular swelling and tibial thrust of the left stifle.

INVOICE

57965

INTERPRETATION OF THE FINDINGS & FURTHER RECOMMENDATIONS

DATE

4-24-23

The radiographic study appears to parallel the clinical history of cruciate ligament injury with mild cranial thrust of the tibia and articular swelling which can represent effusion, hemorrhage, synovial swelling, or a combination of these. No evidence of degenerative joint disease is seen at this point.



PATIENT

Toby Porter

SPECIES

Canine

BREED

Blue Heeler

SEX

Male

AGE

1 Year, 8 Months

INTERPRETED BY

Nele Eley, DVM
Dr. med. Vet. DipECVDI

HOSPITAL NAME

Elizabeth Animal
Hospital

REFERRING VET

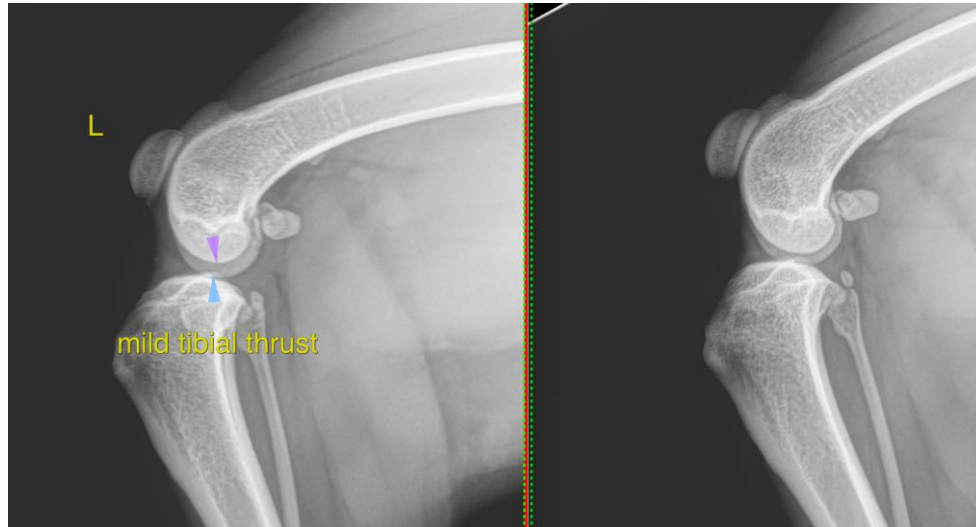
Leon Anderson, DVM

INVOICE

57965

DATE

4-24-23



The information and recommendations provided are based on the images presented by the referring veterinarian/sonographer. No evaluation can be communicated regarding pathology that was not visible in the image/video clips provided.

Thank you for this referral. If the clinical or image interpretation does not parallel your findings or if I can be of any further assistance please contact me.

Nele Eley, DVM, Dr. med. vet., DipECVDI
European Specialist in Veterinary Diagnostic Imaging, Cert. Radiology,
Senior lecturer University of Giessen, Germany, Veterinary Faculty, Department of Radiology
Nele.Eley@sonopath.com