



PATIENT

Noah Delvecchio

PRESENTING CLINICAL SIGNS

Beginning of April toe touching lameness on right hind. O unsure of what happened.
Abnormal PE/Chem/CBC/UA Results: questionable drawer sign on left, right side anterior thrust

SPECIES

Canine

RADIOGRAPHIC STUDY OF THE STIFLES & PELVIS

Mediolateral views of both stifles and ventrodorsal hip extended view of the pelvis totaling 3 images available for review.

BREED

Havanese

RADIOGRAPHIC FINDINGS

Stifles

Moderate articular swelling of the right stifle joint with mild cranial thrust of the tibia is seen. The patella is in situ. A mild amount of periarticular osteophytes is noted.

SEX

Male Neutered

There is mild disuse atrophy of the right hind limb musculature.

AGE

9 Years

The left stifle joint presents within normal limits.

No evidence of atrophy of the left hind limb musculature is noted.

INTERPRETED BY

Nele Eley, DVM
Dr. med. Vet. DipECVDI

The smaller medial fabella is in a distal position which is a normal anatomic variant in terrier and Havanese breeds.

Pelvis

The pelvic bones present within normal limits.

HOSPITAL NAME

The Pet Hospital of
Stratford

Both femoral heads are round and deeply situated within the acetabulum. The right acetabulum is slightly shallow in appearance due to the mild right sided pelvic tilt.

No evidence of osteoarthritic changes is seen.

REFERRING VET

Dr. Claudia Giuliani,
DVM

RADIOGRAPHIC DIAGNOSIS

- Right stifle arthropathy with signs of osteoarthritis and cruciate ligament injury.
- Disuse atrophy of the right hind limb musculature.
- Radiographically normal left stifle and coxofemoral joints.

INVOICE

57951

INTERPRETATION OF THE FINDINGS & FURTHER RECOMMENDATIONS

The radiographic findings support the presence of cruciate ligament injury within the right stifle joint. Mild to moderate osteoarthritic changes of the right stifle joint are seen and there is mild disuse atrophy of the right hind limb musculature.

DATE

4-24-23

The radiographic presentation of the coxofemoral joints and left stifle joint was within normal limits.



PATIENT

Noah Delvecchio

SPECIES

Canine

BREED

Havanese

SEX

Male Neutered

AGE

9 Years

INTERPRETED BY

Nele Eley, DVM
Dr. med. Vet. DipECVDI

HOSPITAL NAME

The Pet Hospital of
Stratford

REFERRING VET

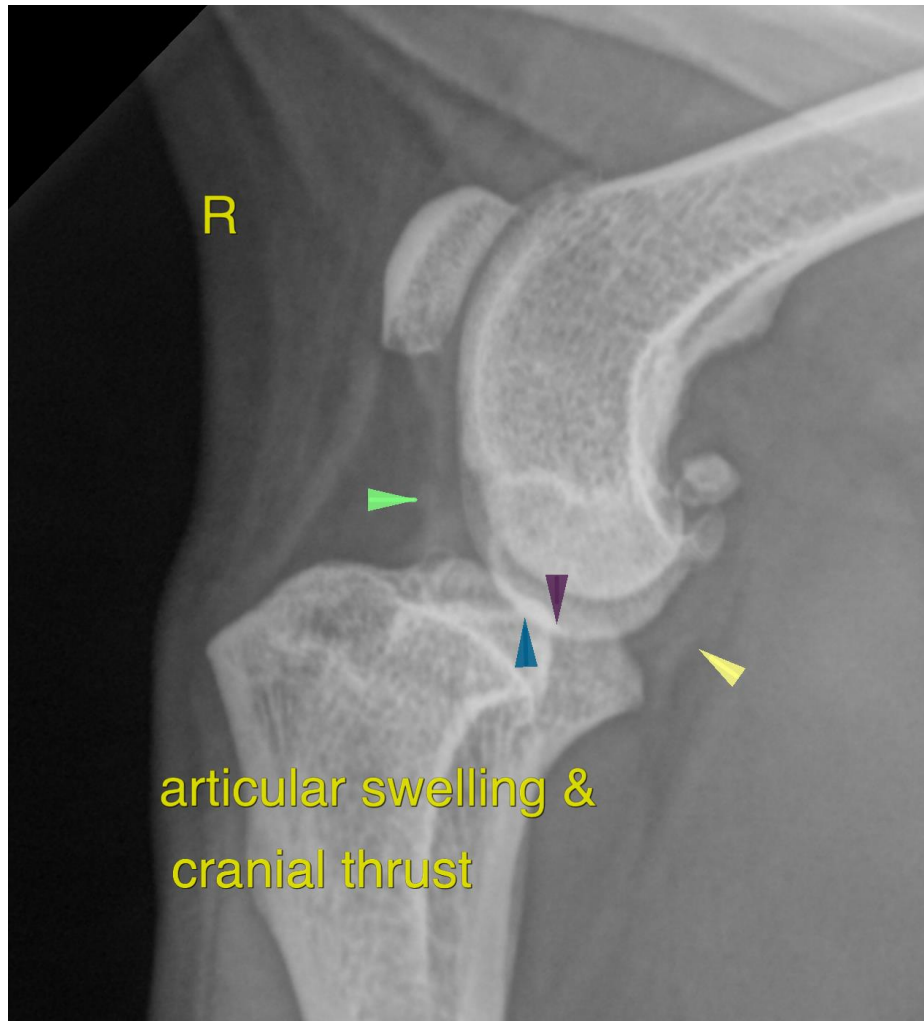
Dr. Claudia Giuliani,
DVM

INVOICE

57951

DATE

4-24-23



The information and recommendations provided are based on the images presented by the referring veterinarian/sonographer. No evaluation can be communicated regarding pathology that was not visible in the image/video clips provided.

Thank you for this referral. If the clinical or image interpretation does not parallel your findings or if I can be of any further assistance please contact me.

Nele Eley, DVM, Dr. med. vet., DipECVDI
European Specialist in Veterinary Diagnostic Imaging, Cert. Radiology,
Senior lecturer University of Giessen, Germany, Veterinary Faculty, Department of Radiology
Nele.Eley@sonopath.com