



**PATIENT**

Boggie Lio

**PRESENTING CLINICAL SIGNS**

Coughing is often, but getting worse. Heart murmur 3/6.

**SPECIES**

Canine

**RADIOGRAPHIC STUDY OF THE THORAX**

Right/left lateral and ventrodorsal views of the thorax totaling 3 images available for review.

**BREED**

Mix

**RADIOGRAPHIC FINDINGS**

The degree of pulmonary inflation is moderate. Mild peribronchial cuffing is seen in the caudodorsal lung field.

**SEX**

Male

Left hand sided cardiomegaly with basico-apical enlargement of the cardiac silhouette and left atrial tenting is noted. The vertebral heart score is 11. No evidence of pulmonary venous congestion and no evidence of cardiogenic pulmonary edema is seen.

The caudal cervical trachea presents moderate collapse on the right lateral view level with the thoracic inlet.

**AGE**

17 Years

Elbow osteoarthritis is noted.

**RADIOGRAPHIC DIAGNOSIS**

- Mild left sided cardiomegaly with no evidence of congestive cardiac failure.
- Dynamic tracheal disease.
- Mild caudodorsally accentuated peribronchial cuffing.

**INTERPRETED BY**

Nele Eley, DVM  
Dr. med. Vet. DipECVDI

**INTERPRETATION OF THE FINDINGS & FURTHER RECOMMENDATIONS**

**HOSPITAL NAME**

Four Corners  
Veterinary Practice

The radiographic study reveals mild left sided cardiomegaly with no evidence of cardiogenic pulmonary edema. The left atrium appears to be enlarged and may cause a mass effect onto the left main stem bronchus which can contribute to coughing. However, there is also evidence of dynamic tracheal disease as well as peribronchial cuffing which is likely to reflect lower airway disease such as eosinophilic / allergic bronchopneumopathy or infectious bronchitis.

**REFERRING VET**

Melina Maritato

Endoscopy with airway sampling could be considered for further definition as well as a cardiac echo depending on the clinical correlation.

**INVOICE**

57952

**DATE**

4-24-23



**PATIENT**

Boggie Lio

**SPECIES**

Canine

**BREED**

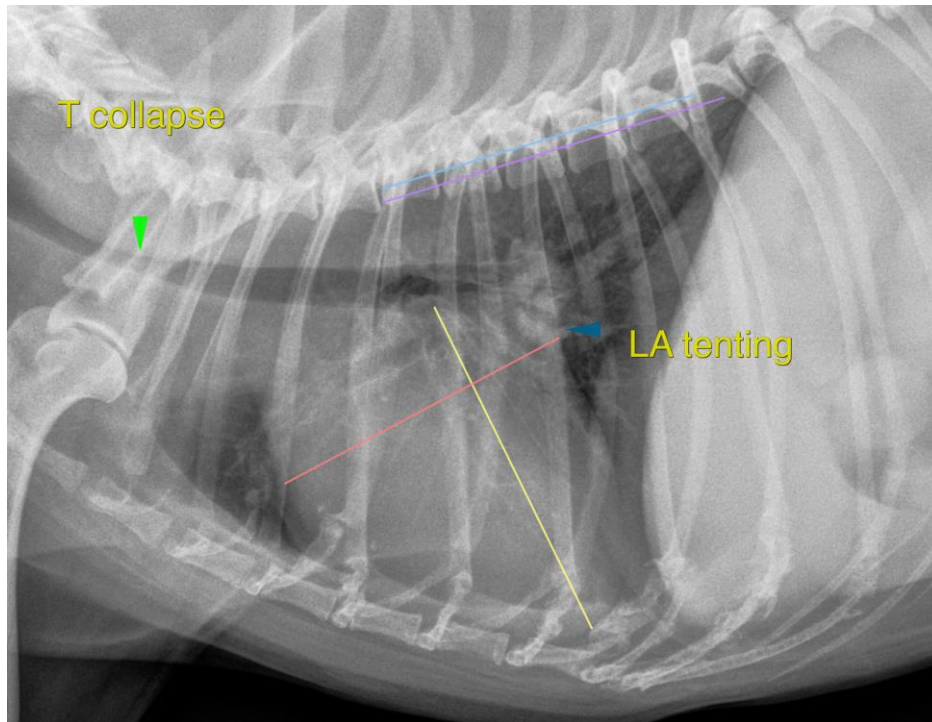
Mix

**SEX**

Male

**AGE**

17 Years



**INTERPRETED BY**

Nele Eley, DVM  
Dr. med. Vet. DipECVDI

**HOSPITAL NAME**

Four Corners  
Veterinary Practice

**REFERRING VET**

Melina Maritato

**INVOICE**

57952

**DATE**

4-24-23

The information and recommendations provided are based on the images presented by the referring veterinarian/sonographer. No evaluation can be communicated regarding pathology that was not visible in the image/video clips provided.

Thank you for this referral. If the clinical or image interpretation does not parallel your findings or if I can be of any further assistance please contact me.

**Nele Eley**, DVM, Dr. med. vet., DipECVDI  
European Specialist in Veterinary Diagnostic Imaging, Cert. Radiology,  
Senior lecturer University of Giessen, Germany, Veterinary Faculty, Department of Radiology  
Nele.Eley@sonopath.com