



**PATIENT PRESENTING CLINICAL SIGNS**

Cowboy Ariola

Cowboy presents today for unable to "meow" loudly. He has had an altered meow for the past week. Per O slight decrease in appetite. with in the past week p is seeming to "loose his voice". decline in activity, sleeping more. O says making a "gurgle sound" while sleeping, but no increase or decrease in respiratory effort. Indoor/Outdoor. Medical Hx: Arrhythmia, HCM EDUD: Eat- slight decrease. Drink- no increase or decreased observed. NO changes. BM/UR- Per O WNL behaviors at home. C/S: none V/D: vomited twice a few days ago Energy: Slight decrease, not lethargic. Diet: Canned Diet, and constantly changing. Rx: none OTC or Dr. Rx. Loss/change of meow: r/o benign vs malignant neoplasia, FHV, other

**SPECIES**

Feline

**BREED**

DSH

**RADIOGRAPHIC STUDY OF THE THORAX**

Right lateral, left lateral and ventrodorsal views totaling three images are available for review.

**SEX**

MN

**RADIOGRAPHIC FINDINGS**

The patient's body condition score is excessive.

Moderate to severe thoracic and lumbar spondyloses are seen.

**AGE**

16yr

Age related cranial rotation of the cardiac silhouette and redundancy of the aortic arch is seen. The vertebral heart score is 8. There is no evidence of cardiomegaly or atrial enlargement. No significant mediastinal widening is seen.

**INTERPRETED BY**

Nele Eley (Ondreka),  
DVM Dr. med. vet.,  
DipECVDI

There is mild flattening of the trachea with redundancy of the dorsal trachea ligament level with the cranial thoracic aperture which appears to be influenced by the position of the head in relation to the thorax and increases with extended head positions.

The degree of pulmonary inflation is moderate. A mild generalized bronchia line pattern is noted with even distribution throughout the lung.

Mild aerophagia is noted within the stomach.

**HOSPITAL NAME**

DTLAvets

Osteoarthritic changes of the elbows are noted.

**RADIOGRAPHIC DIAGNOSIS**

**REFERRING VET**

Dr. Montoya

- Normal age related thorax.
- Redundancy of the dorsal trachea ligament.
- Aerophagia.
- Multiple spondyloses.
- Bilateral elbow osteoarthritis.

**INVOICE**

13568ag

**INTERPRETATION OF FINDINGS & FURTHER RECOMMENDATIONS**

The radiographic findings of the thorax are within age related normal limits. No significant cardiovascular or bronchopulmonary changes are seen.

**DATE**

04/23/2023

The mild flattening of the trachea appears to be a function of the head position. Mild redundancy of



**PATIENT** the dorsal tracheal ligament is noted and is typically an incidental finding.

Cowboy Ariola The aerophagia is likely due to general excitement, pain or respiratory distress.

**SPECIES**

Feline

**BREED**

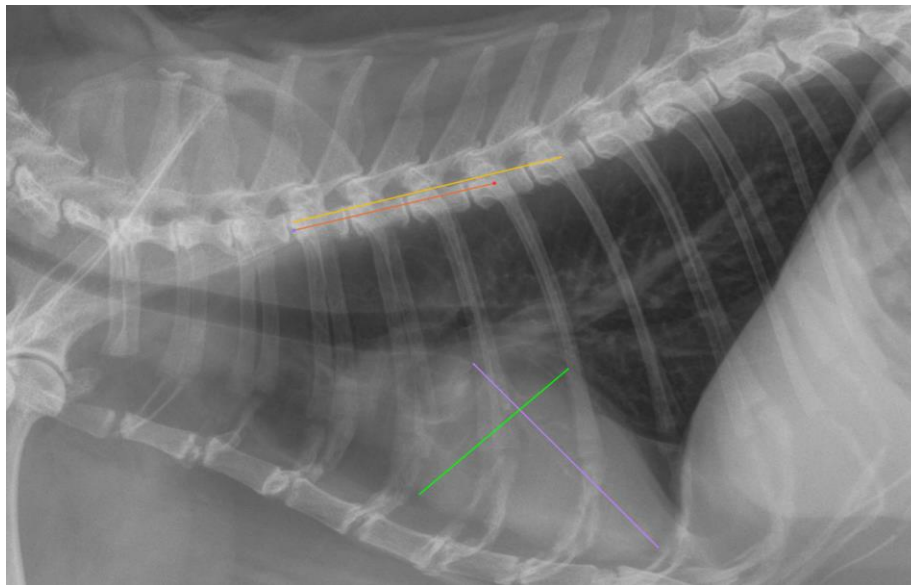
DSH

**SEX**

MN

**AGE**

16yr



**INTERPRETED BY**

Nele Eley (Ondreka),  
DVM Dr. med. vet.,  
DipECVDI

The information and recommendations provided are based on the images presented by the referring veterinarian. No evaluation can be communicated regarding pathology that was not visible in the image/video clips provided.

Thank you for this referral. If the clinical or image interpretation does not parallel your findings or if I can be of any further assistance please contact me.

**HOSPITAL NAME**

DTLAvets

**Nele Eley (Ondreka)**, DVM, Dr. med. vet., DipECVDI  
European Specialist in Veterinary Diagnostic Imaging, Cert. Radiology,  
Senior lecturer University of Giessen/Germany, Veterinary Faculty, Department of Radiology.  
Nele.Eley@sonopath.com

**REFERRING VET**

Dr. Montoya

**INVOICE**

13568ag

**DATE**

04/23/2023