



PATIENT

Ivory Kirkup

SPECIES

Canine

BREED

Pitbull Mix

SEX

FS

AGE

4

WEIGHT

25

INTERPRETED BY

Nele Eley (Ondreka),
DVM Dr. med. vet.,
DipECVDI

IMAGING PERFORMED BY

David

HOSPITAL NAME

Animal Surgical Center
- Oceanside

REFERRING VET

Short

INVOICE

74711

DATE

4-22-26

PRESENTING CLINICAL SIGNS

Alert/appropriate, no CP deficits pelvic limbs, no motor, intact pain sensation, no neck/back pain today
Ambulatory x 2, no palpable orthopedic injury, normal musculature, not using pelvic limbs

COMPUTED TOMOGRAPHIC STUDY OF THE THORACOLUMBAR SPINE

Plain study and myelogram with lumbar puncture at L4/5 available for review. Stack stitching artifacts are noted.

COMPUTED TOMOGRAPHIC FINDINGS

At T12/13 and T13/L1, there are mild intervertebral disc herniations resulting in extradural attenuation and effacement of the ventral subarachnoid space. The dorsal subarachnoid space remains preserved at T12/13 and T13/L1 and there is no significant spinal cord compression. No deviation or dilation of the contrast column and no evidence of severe extradural mass effect noted.

The remaining thoracic and lumbar intervertebral disc spaces are unremarkable.

Mild degenerative changes are present at the lumbosacral junction including mild intervertebral disc protrusion and spondylosis deformans. These changes result in mild lumbosacral canal narrowing without convincing evidence of significant neural compression. The contrast column is continuous and well defined throughout the examined regions aside from the mild ventral effacement described above. No intradural or intramedullary abnormalities can be identified.

The urinary bladder is severely distended.

COMPUTED TOMOGRAPHIC DIAGNOSIS

- Mild intervertebral disc herniations at T12/13 and T13/L1 causing ventral subarachnoid space effacement only.
- No clinically significant spinal cord compression identified.
- Mild degenerative lumbosacral stenosis.

INTERPRETATION OF FINDINGS & FURTHER RECOMMENDATIONS

There is no imaging evidence of a compressive spinal lesion that would explain the reported non ambulatory to paraparesis. The degree of imaging abnormalities is mild and likely incidental or insufficient to explain the severity of neurologic deficits. The negative CT findings render fibrocartilaginous embolic myelopathy, other ischemic myelopathy, and acute noncompressive nucleus pulposus extrusion likely differential diagnoses. Early inflammatory myelopathy is considered less likely but cannot be ruled out entirely. These conditions can result in severe neurologic deficits without significant compression on CT/myelography.

MRI of the thoracolumbar spine can be considered for further evaluation in case of persisting or deteriorating clinical signs.



PATIENT

Ivory Kirkup

SPECIES

Canine

BREED

Pitbull Mix

SEX

FS

AGE

4

WEIGHT

25

INTERPRETED BY

Nele Eley (Ondreka),
DVM Dr. med. vet.,
DipECVDI

IMAGING PERFORMED BY

David

HOSPITAL NAME

Animal Surgical Center
- Oceanside

REFERRING VET

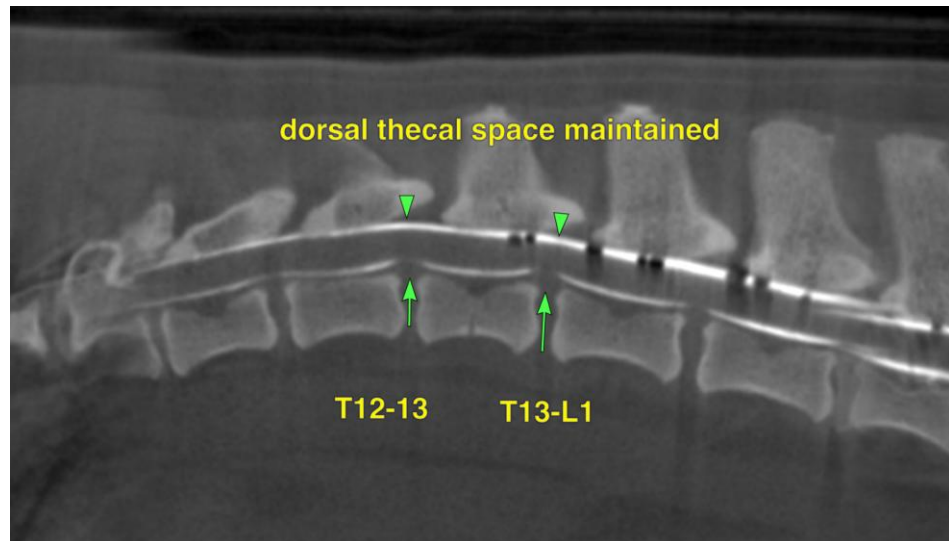
Short

INVOICE

74711

DATE

4-22-26



The information and recommendations provided are based on the images presented by the referring veterinarian. No evaluation can be communicated regarding pathology that was not visible in the image/video clips provided.

Thank you for this referral. If the clinical or image interpretation does not parallel your findings or if I can be of any further assistance please contact me.

Nele Eley (Ondreka), DVM, Dr. med. vet., DipECVDI
European Specialist in Veterinary Diagnostic Imaging, Cert. Radiology,
Senior lecturer University of Giessen/Germany, Veterinary Faculty, Department of Radiology.
info@sonopath.com