

**PATIENT**

Penny Hack

**PRESENTING CLINICAL SIGNS**

History: hind limbs: muscle tremors, fasciculation, (appears to be having pain?)  
Abnormal PE/Chem/CBC/UA Results: Physical Examination Key -- (N= Normal, A= Abnormal)  
Hydration: N Mentation: N EENT: N Oral Cavity: tartar 0-1/4 Lymph Nodes: N Skin: N  
CV/Respiratory: Noisy brachycephalic Abd/GI: N Uro/Perineum: N Musculoskeletal: abnormal posture hindlimbs extended backwards (ie legs at times are not directly under body Neurological: knuckling over hindlegs, especially on (L) hind leg (duration/delay 4 to 6 seconds before righting the paw)

**SPECIES**

Canine

**BREED**

French Bulldog

**RADIOGRAPHIC STUDY OF THE THORACOLUMBAR SPINE**

Lateral and ventrodorsal views of the thoracic and lumbar spine totaling 2 images available for review.

**SEX**

SF

**RADIOGRAPHIC FINDINGS**

The intervertebral disc space L3/4 presents moderate narrowing.  
T4, T5, T6, T8, T9, and T10 appear to be hemi- and short vertebrae.

**AGE**

4 Years, 4 Months

Mild spondylosis deformans is seen between T4 and T5, and T7 and T8.  
There is mild mid thoracic kyphosis.

**INTERPRETED BY**

Nele Eley, DVM  
Dr. med. Vet. DipECVDI

**RADIOGRAPHIC DIAGNOSIS**

- Suspect intervertebral disc disease L3/4.
- Multiple congenital vertebral malformation and mild kyphosis of the thoracic spine.

**HOSPITAL NAME**

DPC Veterinary  
Hospital

**INTERPRETATION OF THE FINDINGS & FURTHER RECOMMENDATIONS**

The radiographic findings suggest potential for intervertebral disc disease within the mid lumbar spine between L3 and L4. The changes may reflect degenerative disc disease as well as disc herniation and further definition by means of cross-sectional imaging is recommended in case of persisting or deteriorating clinical signs.

**REFERRING VET**

Dr. Weekes

**INVOICE**

57937

**DATE**

4-22-23



**PATIENT**

Penny Hack

**SPECIES**

Canine

**BREED**

French Bulldog

**SEX**

SF

**AGE**

4 Years, 4 Months

**INTERPRETED BY**

Nele Eley, DVM  
Dr. med. Vet. DipECVDI

**HOSPITAL NAME**

DPC Veterinary  
Hospital

**REFERRING VET**

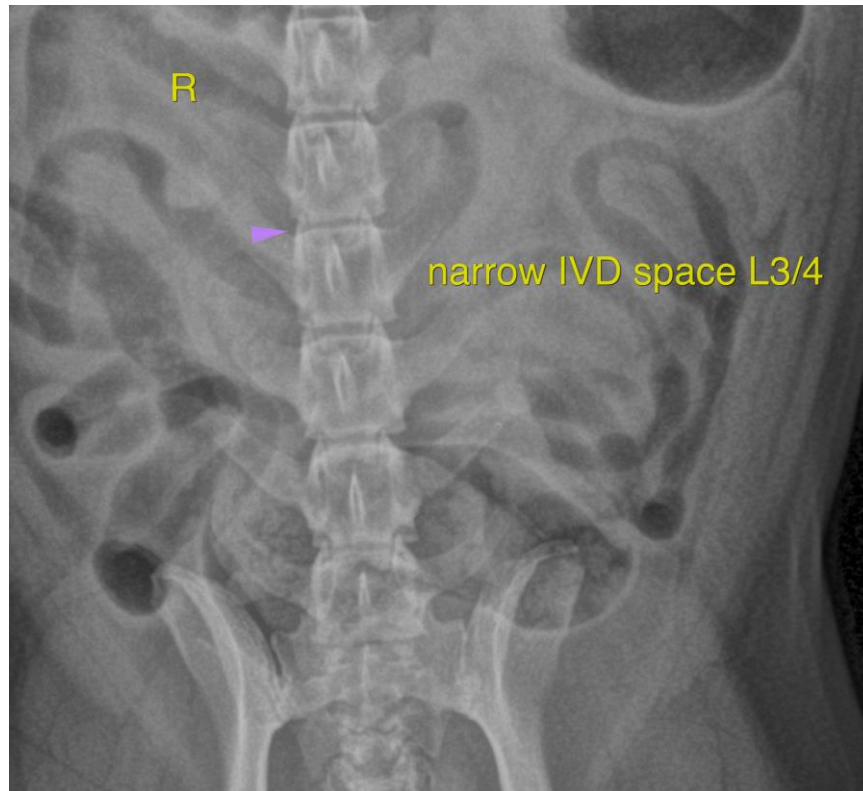
Dr. Weekes

**INVOICE**

57937

**DATE**

4-22-23



The information and recommendations provided are based on the images presented by the referring veterinarian/sonographer. No evaluation can be communicated regarding pathology that was not visible in the image/video clips provided.

Thank you for this referral. If the clinical or image interpretation does not parallel your findings or if I can be of any further assistance please contact me.

**Nele Eley**, DVM, Dr. med. vet., DipECVDI  
European Specialist in Veterinary Diagnostic Imaging, Cert. Radiology,  
Senior lecturer University of Giessen, Germany, Veterinary Faculty, Department of Radiology  
Nele.Eley@sonopath.com