



**PATIENT PRESENTING CLINICAL SIGNS**

Cookie Wong  
**SPECIES** Canine  
**BREED** Shih Tzu  
**SEX** SF

History 4/21/23: 3 year 6 month S/F maltese mix presented today for vomiting. P started to vomit around 4 am this morning and has vomited about 4 more times since. O says P is vomiting foamy white. O says P is lethargic and licking lips. P did not eat or drink this morning but P was acting normal prior to P starting to vomit. O says last night whe P was coming inside from outside P was being swarmed by mosquitos. P did lose some weight O did cut back on food to lose weight. no other concerns. History 4/22/23: P not eat at all refusing all food offered and being hand fed. O says p was more lethargic after yesterdays visit and P bowel was redish and brown with some mucus after leaving the office. P drank water last night and this morning. O did not give cerenia says because p wasnt vomiting and did not give pedialyte. o did give sucralfate last night and this morning.

Abnormal PE/Chem/CBC/UA Results: Physical Examination Key -- (N= Normal, A= Abnormal)  
 Hydration: N Mentation: depressed/quiet EENT: mild clear ocular discharge OU Oral Cavity: mild calculus 0-1/4 Lymph Nodes: N Skin: N CV/Respiratory: N Abd/GI: was tensed/taut on palpation (didn't grunt on palpation, but was uncomfortable) Uro/Perineum: N Musculoskeletal: N Neurological: N Fecal: Diagnostic Testing Needed: CBC/Chem w/lytes: unremarkable and mostly wnl cPL Snap: NEG Fecal: NOPS

**RADIOGRAPHIC STUDY OF THE ABDOMEN**

**AGE** Right/left lateral and ventrodorsal views of the abdomen totaling 3 images available for review.

3 Years, 6 Months

**RADIOGRAPHIC FINDINGS**

**INTERPRETED BY** There appears to be medial patella luxation in the right stifle joint.

Nele Eley, DVM  
 Dr. med. Vet. DipECVDI  
 No abnormalities of the extraabdominal soft tissues are noted. The abdominal wall is smooth and thin.

**HOSPITAL NAME** The serosal detail is maintained throughout the peritoneal and retroperitoneal space.

DPC Veterinary Hospital The liver is appropriate in position, size and presents uniform opacity.

The splenic head is in the anticipated position and within normal limits for size and opacity. The splenic body and tail are considered normal for position, size, shape and opacity.

**REFERRING VET** Both kidneys are seen and present with normal size, shape, delineation and opacity. The urinary bladder is in its anticipated position. No radiopaque calculi are noted throughout the upper and lower urinary tract.

Dr. Weekes  
 Mild gastric aerophagia is noted.

**INVOICE** 57941 The small intestinal loops are evenly distributed throughout the mid abdomen with no evidence of abnormal dilation, plication, or radiopaque foreign material.

**DATE** 4-22-23 The colon and cecum contain gas and no fecal matter is seen within the large intestine.



**PATIENT**

Cookie Wong

**RADIOGRAPHIC DIAGNOSIS**

- Gastrointestinal maldigestion pattern with no evidence of mechanical ileus.

**SPECIES**

Canine

**INTERPRETATION OF THE FINDINGS & FURTHER RECOMMENDATIONS**

The radiographic findings do not suggest presence of obstructive/mechanical intestinal ileus. Functional ileus is considered likely based on the radiographic presentation. Further definition by means of abdominal ultrasound could be considered in case of persisting clinical signs.

**BREED**

Shih Tzu

**SEX**

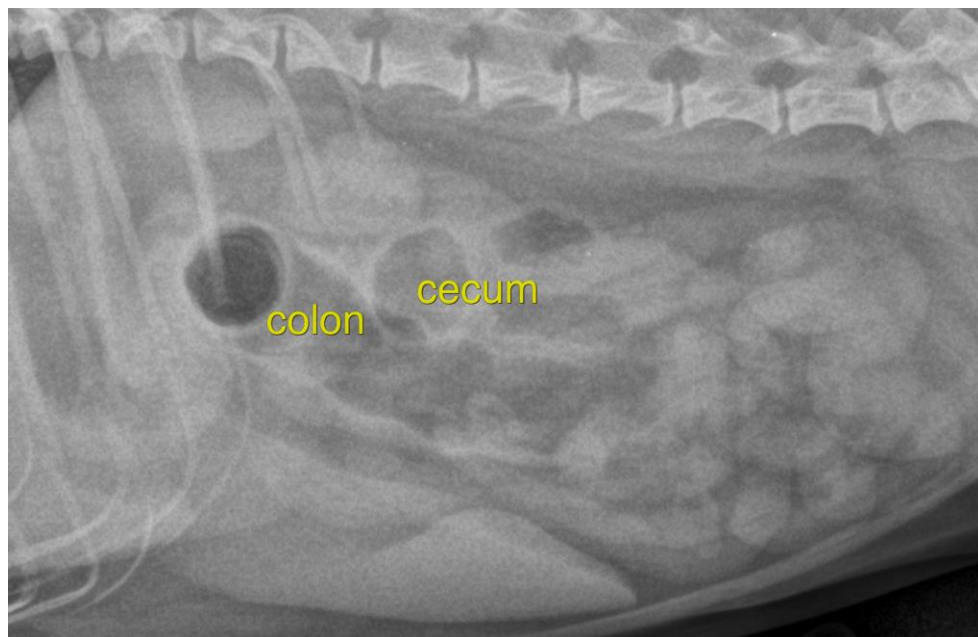
SF

**AGE**

3 Years, 6 Months

**INTERPRETED BY**

Nele Eley, DVM  
Dr. med. Vet. DipECVDI



**HOSPITAL NAME**

DPC Veterinary  
Hospital

**The information and recommendations provided are based on the images presented by the referring veterinarian/sonographer. No evaluation can be communicated regarding pathology that was not visible in the image/video clips provided.**

**REFERRING VET**

Dr. Weekes

Thank you for this referral. If the clinical or image interpretation does not parallel your findings or if I can be of any further assistance please contact me.

**INVOICE**

57941

**Nele Eley, DVM, Dr. med. vet., DipECVDI**  
European Specialist in Veterinary Diagnostic Imaging, Cert. Radiology,  
Senior lecturer University of Giessen, Germany, Veterinary Faculty, Department of Radiology  
Nele.Eley@sonopath.com

**DATE**

4-22-23