



PATIENT

Chuckles Navarette

SPECIES

Canine

BREED

Pekingese Mix

SEX

MN

AGE

5

INTERPRETED BY

Nele Eley, DVM
Dr. med. Vet. DipECVDI

HOSPITAL NAME

Southern Oregon
Veterinary Specialty
Center

REFERRING VET

Dr. Rory Applegate

INVOICE

57943

DATE

4-22-23

PRESENTING CLINICAL SIGNS

History: Chuckles presents to the SOVSC Internal Medicine Service for Neurological concerns and historical management for dyscospondylitis. January 2023 acute neurological deficits following jumping. Concern of left forelimb predominantly affected but o notes trouble with ambulation with all limbs. Treated for inflammatory and infective disease with single steroid injection, 4 month course Amoxicillin-Clavulonate, started SID NSAID support. Deficits and pain resolved. Followup made to further evaluate for any underlying cause or persistent issue. Computed Tomography for Chuckles Navarette Chuckles was anesthetized to examine the spine. An injectable contrast agent was given intravenously, and the scan was repeated. No myelogram performed.

COMPUTED TOMOGRAPHIC STUDY OF THE SPINE

Plain and post IV contrast studies of the cervical, thoracic, and lumbar spine available for review.

COMPUTED TOMOGRAPHIC FINDINGS

General number and anatomy of the cervical, thoracic, and lumbar vertebrae present within normal limits.

A severe mineralized extrusion of intervertebral disc material is seen in the cervical spine between C4 and C5. 70% of the vertebral canal's height is occupied by the extruded material. Severe dorsal deviation and compression of the spinal are present. The intervertebral disc space is moderately collapsed.

Mild partially mineralized intervertebral disc protrusions are seen between T2/3, T12/13, & L4/5.

Multiple intervertebral discs present varying degrees of mineralization.

The craniocervical junction presents within normal limits.

COMPUTED TOMOGRAPHIC DIAGNOSIS

- Severe mineralized intervertebral disc extrusion with spinal cord compression C4/5.
- Chronic mild intervertebral disc protrusions T2/3, T12/13, & L4/5.
- Multiple chondroid disc degeneration.

INTERPRETATION OF THE FINDINGS & FURTHER RECOMMENDATIONS

The CT study reveals severe spinal cord compression secondary to mineralized intervertebral disc protrusion within the cervical spine between C4 and C5. Decompressive surgery could be considered based on the volume of the extrusion and severe spinal cord compression.



PATIENT

Chuckles Navarette

SPECIES

Canine

BREED

Pekingese Mix

SEX

MN

AGE

5

INTERPRETED BY

Nele Eley, DVM
Dr. med. Vet. DipECVDI

HOSPITAL NAME

Southern Oregon
Veterinary Specialty
Center

REFERRING VET

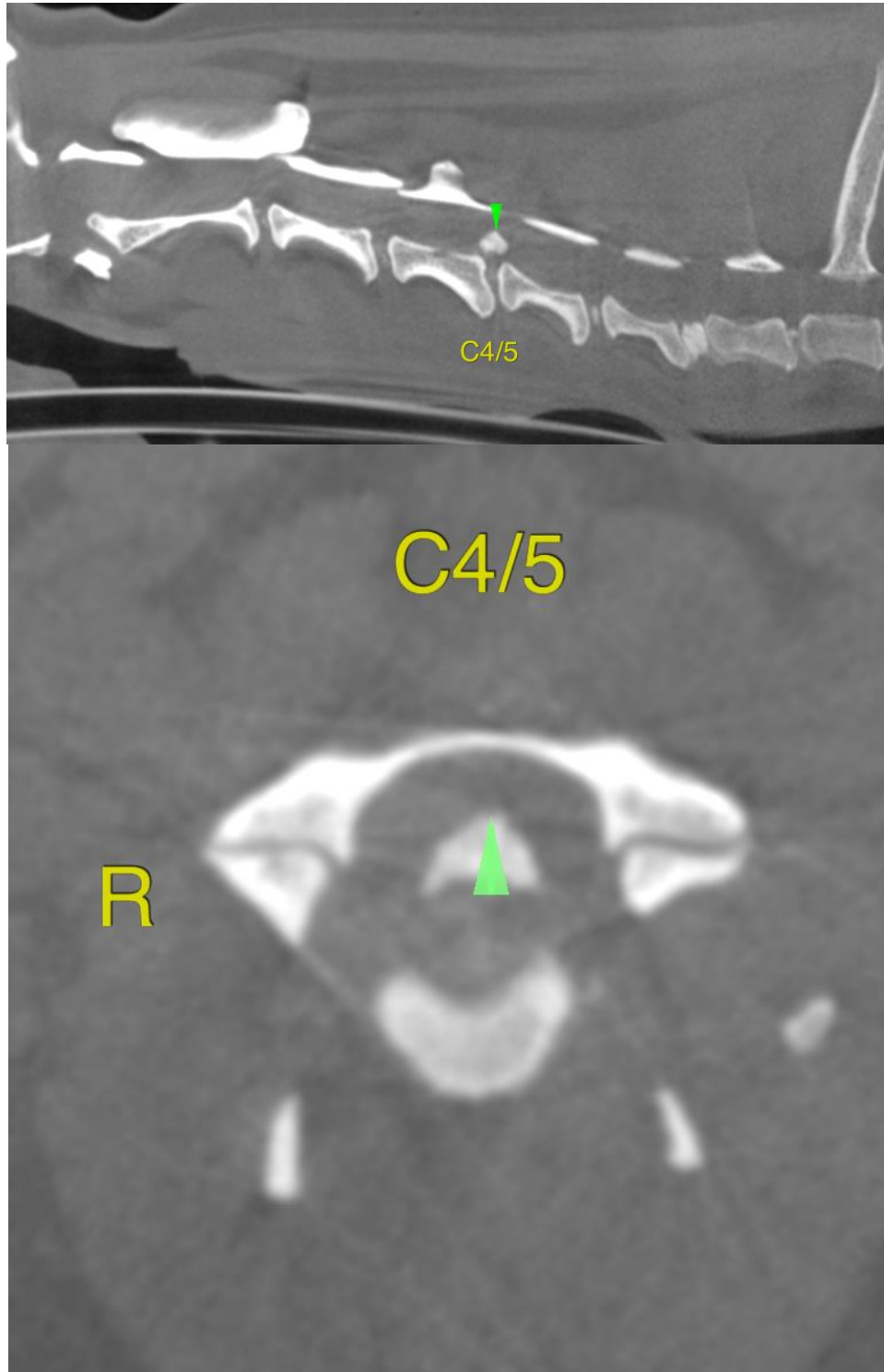
Dr. Rory Applegate

INVOICE

57943

DATE

4-22-23





PATIENT

Chuckles Navarette

The information and recommendations provided are based on the images presented by the referring veterinarian/sonographer. No evaluation can be communicated regarding pathology that was not visible in the image/video clips provided.

Thank you for this referral. If the clinical or image interpretation does not parallel your findings or if I can be of any further assistance please contact me.

SPECIES

Canine

Nele Eley, DVM, Dr. med. vet., DipECVDI
European Specialist in Veterinary Diagnostic Imaging, Cert. Radiology,
Senior lecturer University of Giessen, Germany, Veterinary Faculty, Department of Radiology
Nele.Eley@sonopath.com

BREED

Pekingese Mix

SEX

MN

AGE

5

INTERPRETED BY

Nele Eley, DVM
Dr. med. Vet. DipECVDI

HOSPITAL NAME

Southern Oregon
Veterinary Specialty
Center

REFERRING VET

Dr. Rory Applegate

INVOICE

57943

DATE

4-22-23