



PATIENT PRESENTING CLINICAL SIGNS

PATIENT
Bruce Darland
Acute onset of coughing starting yesterday. SUPER loud, raspy cough with intermittent phlegm production. Very sensitive to tracheal palpation. Has not been at daycare in 3 weeks. Otherwise acting completely normal.

SPECIES
Canine
Abnormal PE/Chem/CBC/UA Results: Very loud, raspy cough induced with tracheal palpation. Wild child, temp is 103.1 but suspect from excitement. Slightly increased bronchovesicular sounds throughout all lung fields, no distinct crackles or wheezes, no areas of decreased percussion. grade 2/6 aortic systolic murmur, pluses strong and synchronous - NOT NEW

BREED RADIOGRAPHIC STUDY OF THE THORAX

BREED
Boxer
Right/left lateral and ventrodorsal views of the thorax totaling 3 images available for review.

RADIOGRAPHIC FINDINGS

SEX
MN
The degree of pulmonary inflation is moderate. A mild bronchointerstitial lung pattern with mild peribronchial cuffing accentuated in the caudodorsal lung field is noted.

Mild redundancy of the dorsal tracheal ligament is seen.

AGE
4 Years
The cardiac silhouette presents within normal limits. No specific chamber and no significant vascular enlargement is seen. The vertebral heart score is 10.3 which is within the reference range that is up to 12 in boxers.

INTERPRETED BY
There is no evidence of mediastinal widening.

Nele Eley, DVM
Dr. med. Vet. DipECVDI
Early spondylosis deformans is present at T5/6.

RADIOGRAPHIC DIAGNOSIS

- Redundant dorsal tracheal ligament
- Mild bronchointerstitial lung pattern.

HOSPITAL NAME

Northshore
Veterinary Hospital

INTERPRETATION OF THE FINDINGS & FURTHER RECOMMENDATIONS

Redundancy of the dorsal tracheal ligament of the thoracic trachea is seen intermittently between the right and left lateral views which typically is an incidental finding, however, can be associated with dynamic tracheal disease.

REFERRING VET

Kristin Williams

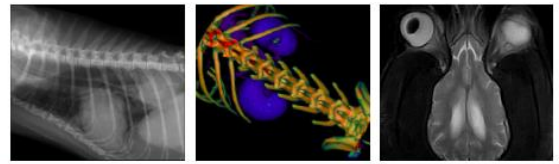
The significance of the mild bronchointerstitial lung pattern is uncertain. These changes may be within age related normal limits. However, lower airway disease such as eosinophilic bronchopneumopathy or infectious bronchitis cannot be ruled out entirely. Further endoscopic workup could be considered.

INVOICE

57939

DATE

4-22-23



PATIENT

Bruce Darland

SPECIES

Canine

BREED

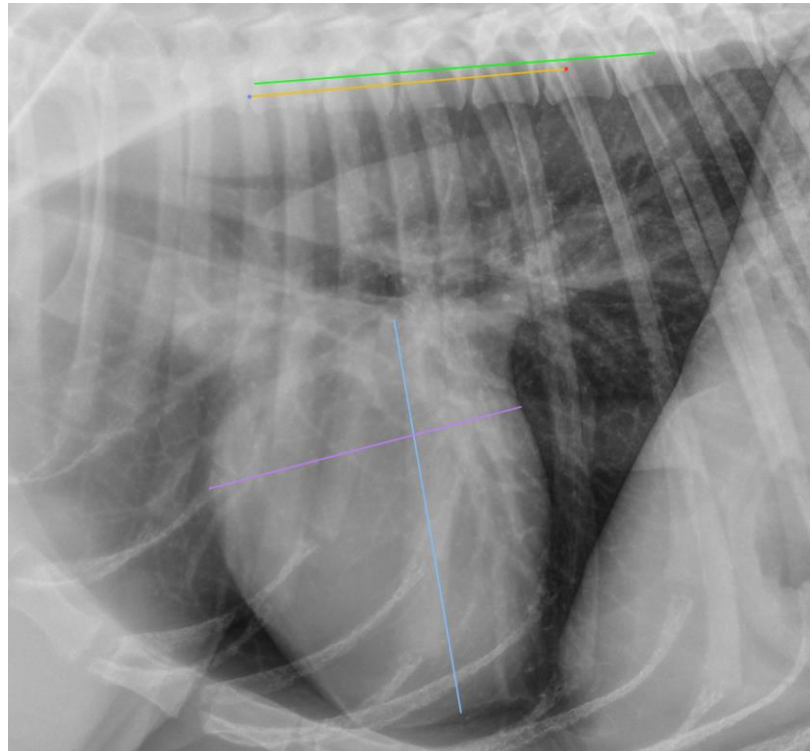
Boxer

SEX

MN

AGE

4 Years



INTERPRETED BY

Nele Eley, DVM
Dr. med. Vet. DipECVDI

The information and recommendations provided are based on the images presented by the referring veterinarian/sonographer. No evaluation can be communicated regarding pathology that was not visible in the image/video clips provided.

HOSPITAL NAME

Northshore
Veterinary Hospital

Thank you for this referral. If the clinical or image interpretation does not parallel your findings or if I can be of any further assistance please contact me.

Nele Eley, DVM, Dr. med. vet., DipECVDI
European Specialist in Veterinary Diagnostic Imaging, Cert. Radiology,
Senior lecturer University of Giessen, Germany, Veterinary Faculty, Department of Radiology
Nele.Eley@sonopath.com

REFERRING VET

Kristin Williams

INVOICE

57939

DATE

4-22-23