



**PATIENT**

Kiki Ma

**PRESENTING CLINICAL SIGNS**

Pre COHAT CT

**SPECIES**

Feline

**COMPUTED TOMOGRAPHIC STUDY OF THE DENTAL ARCADES**

Plain study available for review.

**BREED**

Scottish Straight

**COMPUTED TOMOGRAPHIC FINDINGS**

The dentition is incomplete. Multiple tooth elements are absent. All maxillary and mandibular premolar and molar teeth are absent.

**SEX**

Male Neutered

The dental neck and root of the triadan 104 present severe resorptive changes as well as widening of the periodontium.

Mild resorptive lesions are present at the triadan 204.

**AGE**

12 Years, 10 Months

Severe resorption with severe widening of the periodontium is noted at the triadan 304.

A root remnant of the triadan 201 is seen.

There is a supernumerous incisor in the left mandible which is positioned in a horizontal plane medial to the triadan 304.

**INTERPRETED BY**

Nele Eley, DVM  
Dr. med. Vet. DipECVDI

A root remnant of the triadan 402 is seen.

The alveolar crest presents moderate horizontal atrophy in all quadrants.

There is moderate asymmetry of the calvarium which usually is an incidental finding.

**HOSPITAL NAME**

South Bay Animal  
Hospital & Pet Resort

A mild amount of hypoattenuating material is present within the medial aspect of the right external auditory meatus.

**COMPUTED TOMOGRAPHIC DIAGNOSIS**

**REFERRING VET**

Dr. Atwal

- Incomplete dentition with multifocal FORL and periodontal disease accentuating the triadans 104 and 304.
- Supernumerous incisor medial to the triadan 304.

**INTERPRETATION OF THE FINDINGS & FURTHER RECOMMENDATIONS**

**INVOICE**

51714

Severe resorptive lesions and periodontal disease are associated with the triadans 104 and 304. Milder FORL lesions are present at the dental neck and root of the triadan 204.

**DATE**

4-22-22

The supernumerous incisor in the left mandible is immediately adjacent to the dental neck and crown of the triadan 304.



**PATIENT**

Kiki Ma

**SPECIES**

Feline

**BREED**

Scottish Straight

**SEX**

Male Neutered

**AGE**

12 Years, 10 Months

**INTERPRETED BY**

Nele Eley, DVM  
Dr. med. Vet. DipECVDI

**HOSPITAL NAME**

South Bay Animal  
Hospital & Pet Resort

**REFERRING VET**

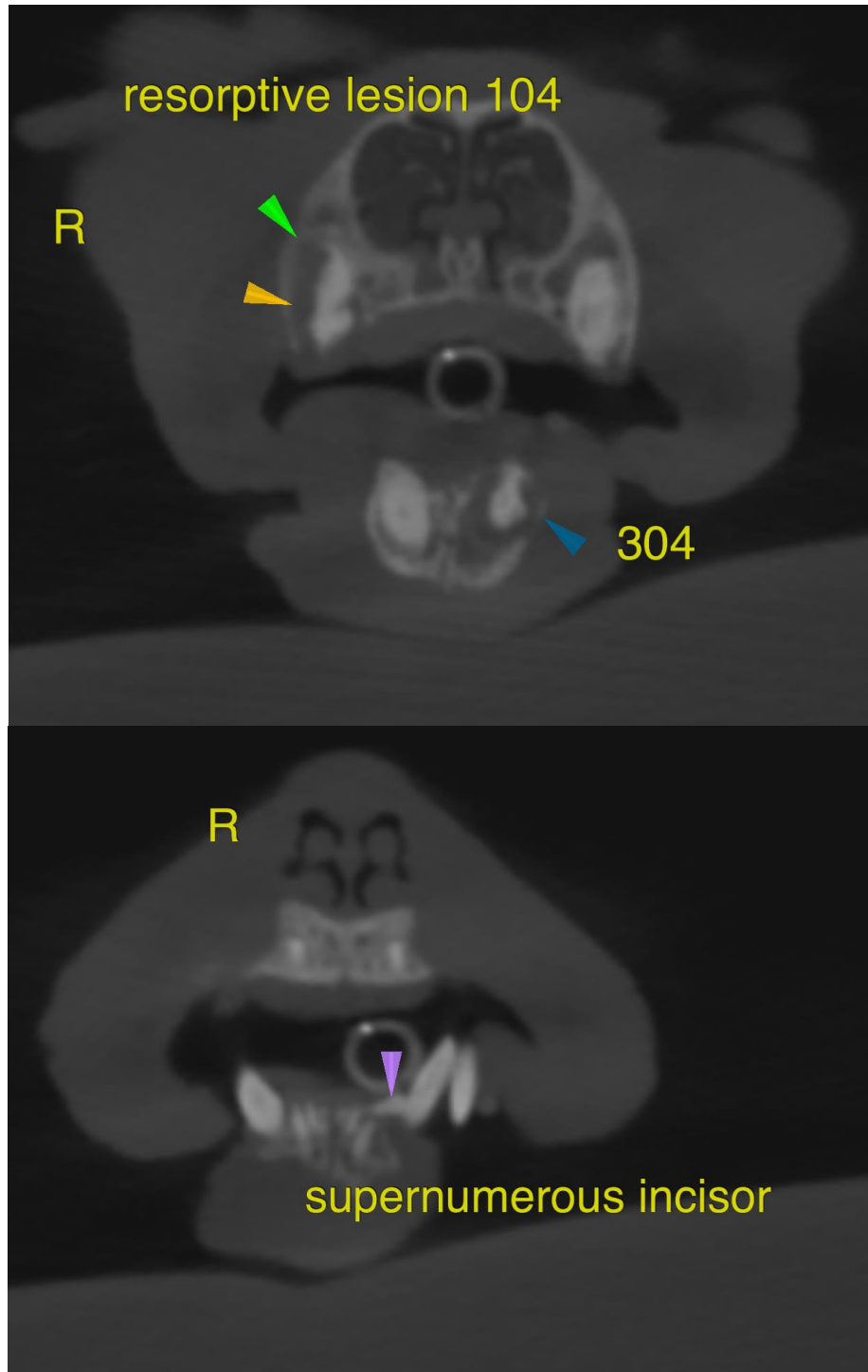
Dr. Atwal

**INVOICE**

51714

**DATE**

4-22-22





**PATIENT**

Kiki Ma

The information and recommendations provided are based on the images presented by the referring veterinarian/sonographer. No evaluation can be communicated regarding pathology that was not visible in the image/video clips provided.

Thank you for this referral. If the clinical or image interpretation does not parallel your findings or if I can be of any further assistance please contact me.

**SPECIES**

Feline

**Nele Eley**, DVM, Dr. med. vet., DipECVDI  
European Specialist in Veterinary Diagnostic Imaging, Cert. Radiology,  
Senior lecturer University of Giessen, Germany, Veterinary Faculty, Department of Radiology  
Nele.Eley@sonopath.com

**BREED**

Scottish Straight

**SEX**

Male Neutered

**AGE**

12 Years, 10 Months

**INTERPRETED BY**

Nele Eley, DVM  
Dr. med. Vet. DipECVDI

**HOSPITAL NAME**

South Bay Animal  
Hospital & Pet Resort

**REFERRING VET**

Dr. Atwal

**INVOICE**

51714

**DATE**

4-22-22