



PATIENT

Vanilla Han

SPECIES

Canine

BREED

Terrier Mix

SEX

FS

AGE

15Y

WEIGHT

6kg

INTERPRETED BY

Nele Eley (Ondreka),
DVM Dr. med. vet.,
DipECVDI

IMAGING PERFORMED BY

Dr. Celestine Hoh

HOSPITAL NAME

My Pet Mobile Vet

REFERRING VET

Dr. Celestine Hoh

INVOICE

74708

DATE

4-21-26

PRESENTING CLINICAL SIGNS

Vanilla Han presents for wellness examination and evaluation of syncope

Patient History:

- Thyroid carcinoma diagnosed in 2025.
- Recent episode one week ago: bruising around thyroid mass with two episodes of syncope
- Bruising has since resolved, no syncope since last week
- Gets extremely fearful at veterinary visits; trazodone makes anxiety worse
- Previous visit to ASEC oncologist resulted in syncope episode due to fear
- Last blood work was mostly normal, advised to monitor kidneys
- Last echocardiogram 6 months ago
- Current medications: pimobendan 1.25mg PO q12h, Furosemide

The owner declines any anesthetic procedures, including thyroid mass surgery, due to P's advanced age and underlying heart disease.

RADIOGRAPHIC STUDY OF THE THORAX

Three view study available for review.

RADIOGRAPHIC FINDINGS

Mild generalized cardiomegaly with mild left atrial enlargement is seen. The VHS is 11. VLAS is 2.1 consistent with mild left sided cardiac enlargement. No significant volume overload and no radiographic evidence of congestive heart failure is present at this time.

The pulmonary parenchyma presents within normal limits for age with no evidence of pulmonary edema, interstitial/alveolar infiltrates, pulmonary nodules, masses, or consolidations.

Mild narrowing of the caudal cervical trachea is seen consistently on the lateral views consistent with mild tracheal collapse.

No mediastinal changes are noted.

The abdomen appears mildly distended and rounded.

RADIOGRAPHIC DIAGNOSIS

- Mild left sided cardiomegaly with mild left atrial enlargement.
- No radiographic evidence of congestive heart failure.
- Mild caudal cervical tracheal collapse.
- Age appropriate pulmonary pattern.

INTERPRETATION OF FINDINGS & FURTHER RECOMMENDATIONS

The findings are most consistent with mild structural cardiac disease in keeping with the patient's non-history and cardiac medication. Absence of pulmonary edema is noted radiographically at this point. Syncope in this patient nevertheless may be cardiogenic (arrhythmia or low output episodes, vasovagal or multifactorial).

The mild tracheal collapse is likely incidental.

Cardiac rehabilitation with echocardiography and ECG could be considered after consultation of a cardiologist.



PATIENT

Vanilla Han

SPECIES

Canine

BREED

Terrier Mix

SEX

FS

AGE

15Y

WEIGHT

6kg

INTERPRETED BY

Nele Eley (Ondreka),
DVM Dr. med. vet.,
DipECVDI

IMAGING PERFORMED BY

Dr. Celestine Hoh

HOSPITAL NAME

My Pet Mobile Vet

REFERRING VET

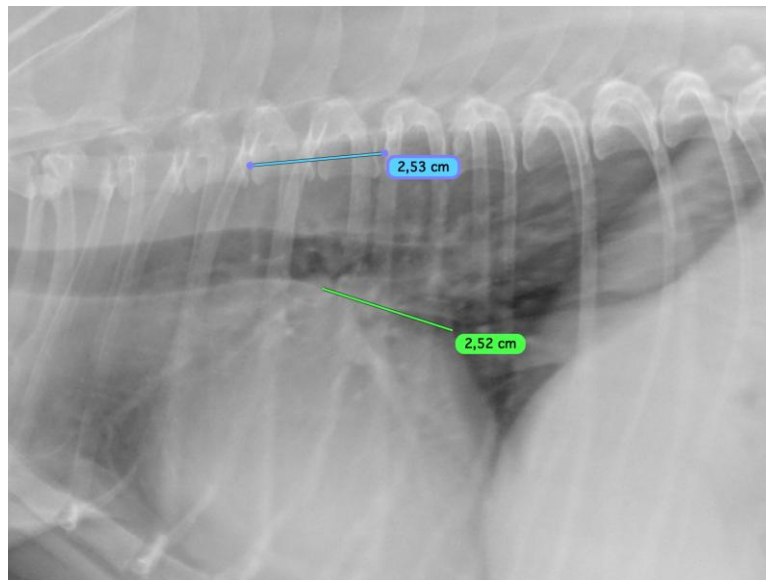
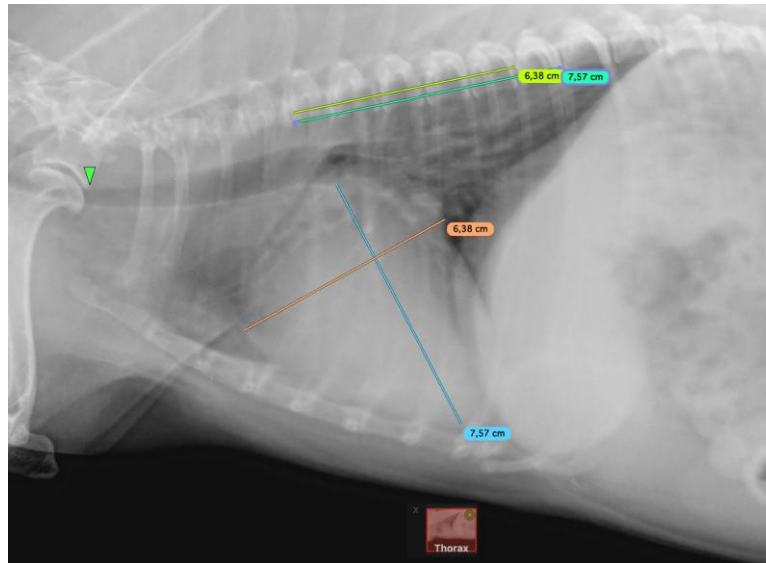
Dr. Celestine Hoh

INVOICE

74708

DATE

4-21-26



The information and recommendations provided are based on the images presented by the referring veterinarian. No evaluation can be communicated regarding pathology that was not visible in the image/video clips provided.

Thank you for this referral. If the clinical or image interpretation does not parallel your findings or if I can be of any further assistance please contact me.

Nele Eley (Ondreka), DVM, Dr. med. vet., DipECVDI
European Specialist in Veterinary Diagnostic Imaging, Cert. Radiology,
Senior lecturer University of Giessen/Germany, Veterinary Faculty, Department of Radiology.
info@sonopath.com