



PATIENT

Rocket Grabow

SPECIES

Canine

BREED

Vizsla

SEX

MN

AGE

12Y, 7M

WEIGHT

65lbs

INTERPRETED BY

Nele Eley (Ondreka),
DVM Dr. med. vet.,
DipECVDF

IMAGING PERFORMED BY

Dr Raul Casas

HOSPITAL NAME

State Avenue Vet
Clinic

REFERRING VET

Dr Raul Casas

INVOICE

74707

DATE

4-21-26

PRESENTING CLINICAL SIGNS

Presents for evaluation of right lower eyelid mass and suspected chronic nasal foreign body.

- Suspected foreign body in left nostril x ~2 yrs; onset after hunting season
 - Left nostril: chapped externally, whistling noise, no progression
 - Right eye: proliferative mass lower eyelid x ~6 mo, intermittent mucoid discharge, pruritus; client cleans daily
 - Previous eye lubricant (unspecified) BID, some improvement
 - Rimadyl 100 mg: 1/2 tab PO SID x ~1 mo, previously PRN for discomfort
 - Chewable supplement with glucosamine
 - No current medications or other supplements
 - No coughing, sneezing, vomiting, or diarrhea reported
 - Annual checkup Jan/Feb 2026; prior vet declined intervention for eyelid mass
 - CT skull: performed, no concerning findings on preliminary review; mild pharyngeal tissue thickening; official report pending
 - Rhinoscopy (bilateral): performed, no significant findings; no mucous, irritation, or foreign body detected
- Abnormal PE/Chem/CBC/UA Results: Sarcopenia present, OD: Proliferative mass lower eyelid, base 3–4 mm, overall 10–12 mm, moderate mucoid discharge, Nostrils slightly dried, Slightly distended abdomen, Stiff gait, Nails long

COMPUTED TOMOGRAPHIC STUDY OF THE NASAL CAVITIES

Plain study available for review.

COMPUTED TOMOGRAPHIC FINDINGS

Mild focal osseous thickening with subtle demineralization involving the left nasal bone dorsocaudal to the nasolacrimal duct opening is seen. This is located in close proximity to the nasal ostium of the nasolacrimal duct. Associated with the region, mild focal mucosal thickening is seen within the adjacent left nasal cavity. No discrete destructive osseous lesion, aggressive lysis, or expansile mass effect is identified. There is no evidence of foreign material within the nasal cavity and radiopaque foreign material can also not be identified within the nasolacrimal duct. No turbinate destruction is seen.

A 14 x 11mm sized proliferative soft tissue mass is present at the right lower eyelid. Orbital contents appear otherwise unremarkable bilaterally.

COMPUTED TOMOGRAPHIC DIAGNOSIS

- Focal osseous remodeling of the left nasal bone with associated mild adjacent mucosal thickening dorsal to the nasolacrimal duct.
- Right lower eyelid soft tissue mass.
- No evidence of nasal foreign body.

INTERPRETATION OF FINDINGS & FURTHER RECOMMENDATIONS

Surgical excision of the right eyelid mass for definitive histopathology is recommended.

The focal osseous thickening with mild adjacent mucosal thickening at the level of the left nasolacrimal duct opening can fit with chronic dacryocystitis/dacryorhinocystitis. Prior trauma is another possible differential diagnosis. Early neoplasia cannot be completely excluded but appears less likely. Flushing



PATIENT

Rocket Grabow

SPECIES

Canine

BREED

Vizsla

SEX

MN

AGE

12Y, 7M

WEIGHT

65lbs

INTERPRETED BY

Nele Eley (Ondreka),
DVM Dr. med. vet.,
DipECVDI

IMAGING PERFORMED BY

Dr Raul Casas

HOSPITAL NAME

State Avenue Vet
Clinic

REFERRING VET

Dr Raul Casas

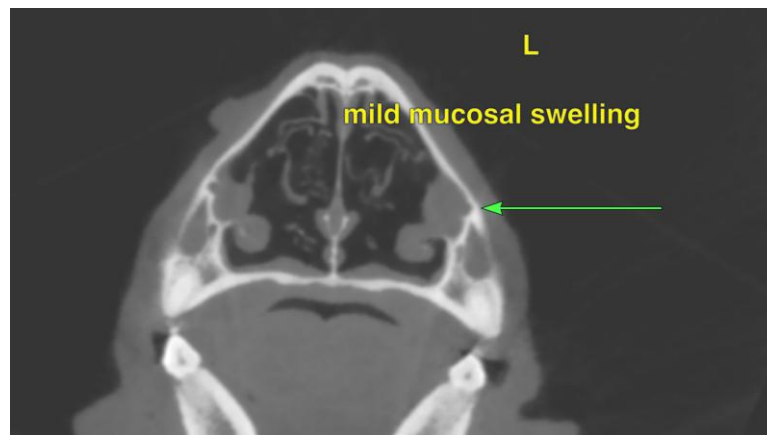
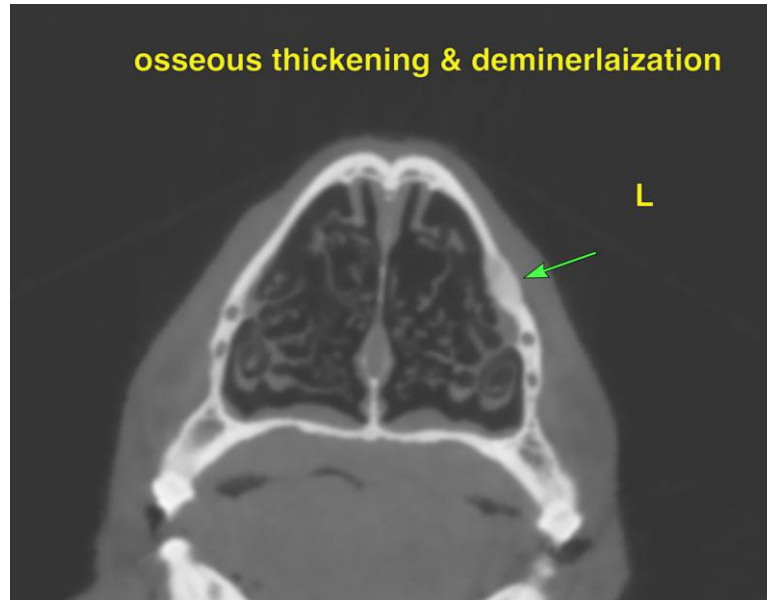
INVOICE

74707

DATE

4-21-26

of the left nasolacrimal duct to be performed to ensure patency. CT dacryorhinocystogram could be performed for further definition as well.





PATIENT

Rocket Grabow

SPECIES

Canine

BREED

Vizsla

SEX

MN

AGE

12Y, 7M

WEIGHT

65lbs

INTERPRETED BY

Nele Eley (Ondreka),
DVM Dr. med. vet.,
DipECVDI

IMAGING PERFORMED BY

Dr Raul Casas

HOSPITAL NAME

State Avenue Vet
Clinic

REFERRING VET

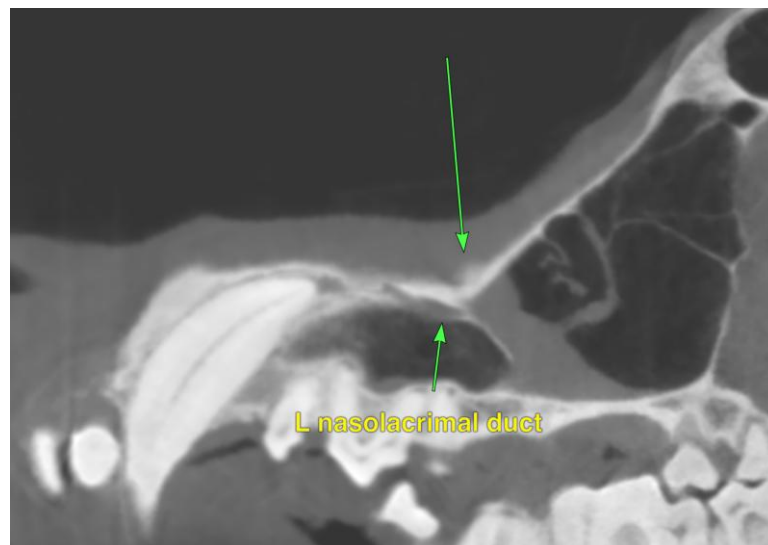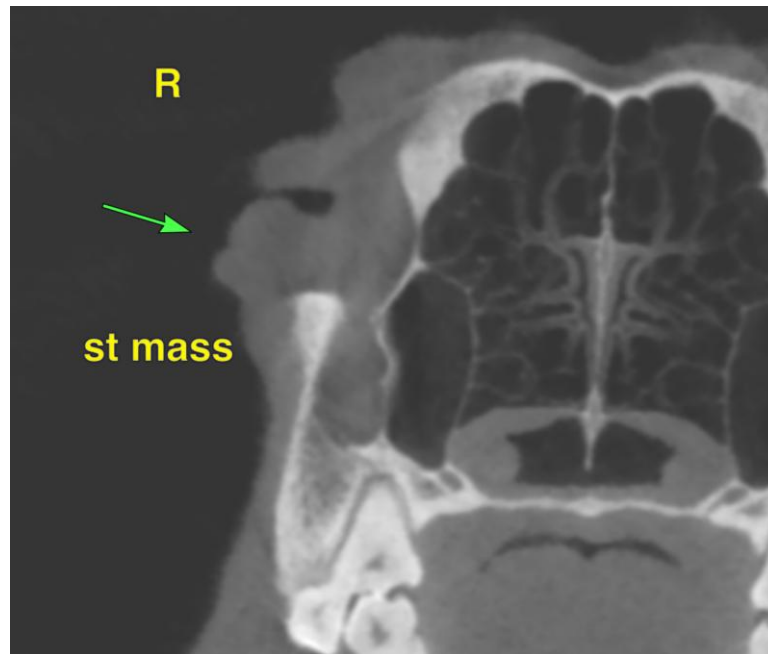
Dr Raul Casas

INVOICE

74707

DATE

4-21-26



The information and recommendations provided are based on the images presented by the referring veterinarian. No evaluation can be communicated regarding pathology that was not visible in the image/video clips provided.

Thank you for this referral. If the clinical or image interpretation does not parallel your findings or if I can be of any further assistance please contact me.

Nele Eley (Ondreka), DVM, Dr. med. vet., DipECVDI
European Specialist in Veterinary Diagnostic Imaging, Cert. Radiology,
Senior lecturer University of Giessen/Germany, Veterinary Faculty, Department of Radiology.
info@sonopath.com