



**PATIENT**

Seamus McManus

**PRESENTING CLINICAL SIGNS**

Was 18 lbs 1/2020, now 10 lbs 9 oz. Somewhat hyporexic. no pu/pd.

**SPECIES**

Feline

**RADIOGRAPHIC STUDY OF THE ABDOMEN**

Left/right lateral and ventrodorsal views of the thorax and abdomen totaling 5 images available for review.

Abdominal read requested.

**BREED**

DSH

**RADIOGRAPHIC FINDINGS**

The patient is in thin body condition.

**SEX**

MN

Thoracolumbar and lumbosacral transitional vertebrae are seen.

Mineral opaque structures superimpose onto the renal diverticuli of both kidneys.

**AGE**

14 Years

The abdominal serosal detail appears to be mildly reduced in the area of the splenic tail and mid abdominal mesentery.

The liver presents within normal radiographic limits.

The colon contains a moderate amount of inspissated fecal matter.

**INTERPRETED BY**

Nele Eley, DVM  
Dr. med. Vet. DipECVDI

**RADIOGRAPHIC DIAGNOSIS**

- Regionally reduced abdominal serosal detail accentuating the mid abdomen.
- Bilateral hypercalcemic nephropathy.
- Dehydration versus constipation of the colon.

**HOSPITAL NAME**

Four Corners  
Veterinary Practice

**INTERPRETATION OF THE FINDINGS & FURTHER RECOMMENDATIONS**

The radiographic study suggests potential for peritoneal effusion or mesenteropathy and further definition by means of abdominal ultrasound is recommended if not performed already.

**REFERRING VET**

Gregory Roccaro

**INVOICE**

51671

**DATE**

4-21-22



**PATIENT**

Seamus McManus

**SPECIES**

Feline

**BREED**

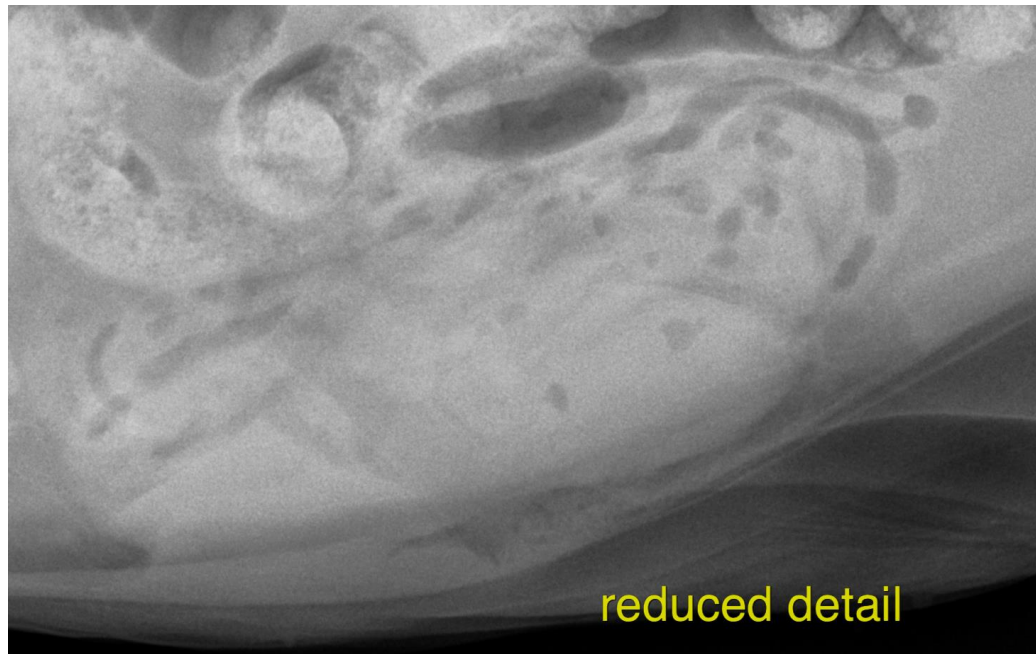
DSH

**SEX**

MN

**AGE**

14 Years



**INTERPRETED BY**

Nele Eley, DVM  
Dr. med. Vet. DipECVDI

The information and recommendations provided are based on the images presented by the referring veterinarian/sonographer. No evaluation can be communicated regarding pathology that was not visible in the image/video clips provided.

Thank you for this referral. If the clinical or image interpretation does not parallel your findings or if I can be of any further assistance please contact me.

**HOSPITAL NAME**

Four Corners  
Veterinary Practice

**Nele Eley**, DVM, Dr. med. vet., DipECVDI  
European Specialist in Veterinary Diagnostic Imaging, Cert. Radiology,  
Senior lecturer University of Giessen, Germany, Veterinary Faculty, Department of Radiology  
Nele.Eley@sonopath.com

**REFERRING VET**

Gregory Roccaro

**INVOICE**

51671

**DATE**

4-21-22