



## PATIENT

Lily Ponensky

## SPECIES

Canine

## BREED

Lab Terrier Mix

## SEX

FS

## AGE

14Y

## WEIGHT

48lbs

## INTERPRETED BY

Nele Eley (Ondreka),  
DVM Dr. med. vet.,  
DipECVDI

## IMAGING PERFORMED BY

Vincent Ravancho,  
CVT

## HOSPITAL NAME

Northvale Veterinary  
Clinic

## REFERRING VET

Dr. Simon

## INVOICE

74677

## DATE

4-20-26

## PRESENTING CLINICAL SIGNS

Limping on (L) hind leg for past few weeks. Hx of CCL repair for (R) leg in 02/2023. Current medications - Trazodone, Gabapentin, Zenrelia, benadryl, Dasuquin, Rimadyl  
Abnormal PE/Chem/CBC/UA Results: ALP 1931, Lymph 0.69. All else WNL

## ULTRASONOGRAPHIC FINDINGS

### Left Stifle

Marked effusion with anechoic fluid is seen within the supra- and infra-patellar recesses of the left stifle joint alongside synovial proliferation and thickening consistent with active synovitis. Mild periarticular osteophytes formation is present.

The cranial cruciate ligament shows hyperechoic interrupted fibers surrounded by a halo of effusion at the intercondylar eminence of the tibia. No intact continuous ligament fibers are identified.

The medial meniscus appears preserved without definitive evidence of displacement, tear, or prolapse.

### Right Stifle

Post-surgical changes consistent with prior extracapsular repair are present.

Suture material is identified in the periarticular soft tissues.

The cranial cruciate ligament is not visualized as a continuous intact structure consistent with prior rupture and surgery.

Only minimal joint effusion is present along with minimal synovial thickening at present.

The medial meniscus appears intact without sonographic evidence of tear or displacement.

Moderate periarticular osteophytes are present.

## ULTRASONOGRAPHIC DIAGNOSIS

### Left Stifle:

- Cranial cruciate ligament rupture with synovitis and osteoarthritis.
- No sonographic evidence of medial meniscal tear at the time of the examination.

### Right Stifle:

- Post-operative status following extracapsular stabilization.
- Mild residual synovitis and minimal effusion.
- No evidence of meniscal pathology.

## INTERPRETATION OF FINDINGS & FURTHER RECOMMENDATIONS

The left stifle findings are consistent with cranial cruciate ligament injury with concomitant inflammatory joint changes and osteoarthritis. Evidence of meniscal injury is not seen ultrasonographically at this point.

On the right, expected post-surgical remodeling is present without evidence of acute synovitis, significant effusion, or meniscal injury.



## PATIENT

Lily Ponensky

## SPECIES

Canine

## BREED

Lab Terrier Mix

## SEX

FS

## AGE

14Y

## WEIGHT

48lbs

## INTERPRETED BY

Nele Eley (Ondreka),  
DVM Dr. med. vet.,  
DipECVDI

## IMAGING PERFORMED BY

Vincent Ravancho,  
CVT

## HOSPITAL NAME

Northvale Veterinary  
Clinic

## REFERRING VET

Dr. Simon

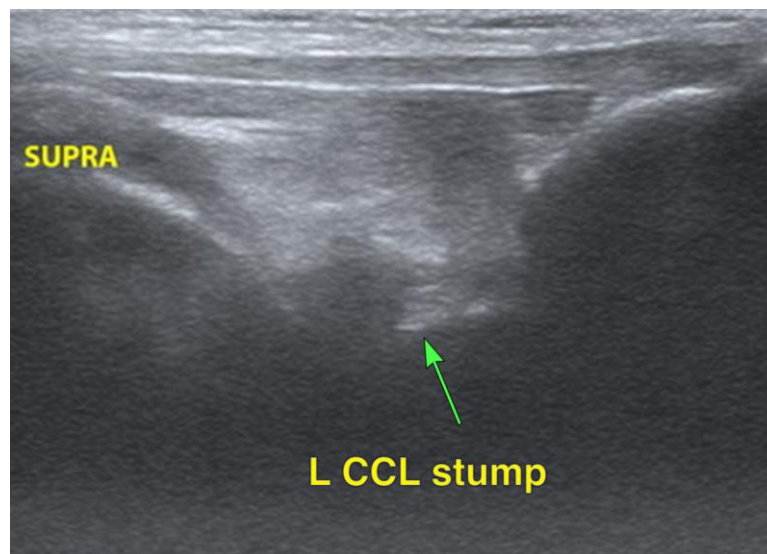
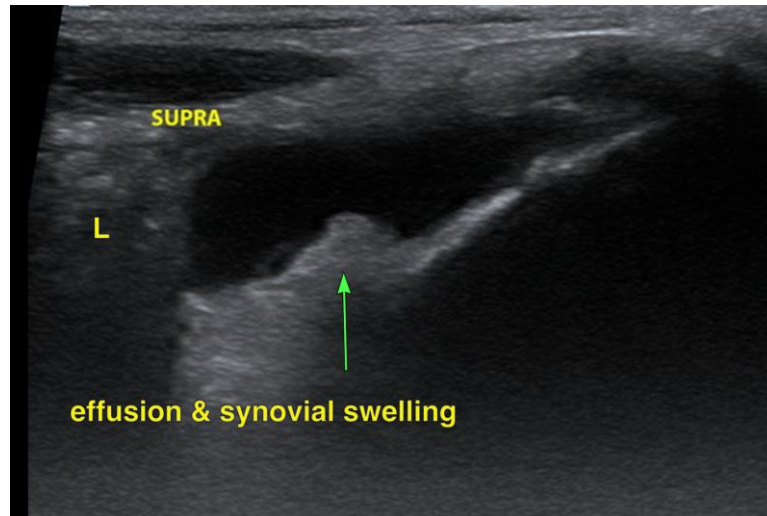
## INVOICE

74677

## DATE

4-20-26

Correlate with orthopedic stability testing and clinical severity. Surgical consultation for the left stifle should be considered.





## PATIENT

Lily Ponensky

## SPECIES

Canine

## BREED

Lab Terrier Mix

## SEX

FS

## AGE

14Y

## WEIGHT

48lbs

## INTERPRETED BY

Nele Eley (Ondreka),  
DVM Dr. med. vet.,  
DipECVDI

## IMAGING PERFORMED BY

Vincent Ravancho,  
CVT

## HOSPITAL NAME

Northvale Veterinary  
Clinic

## REFERRING VET

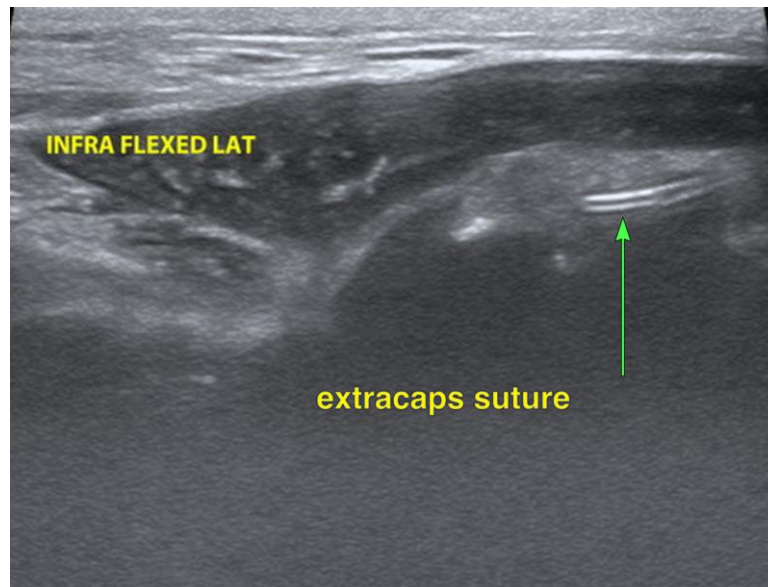
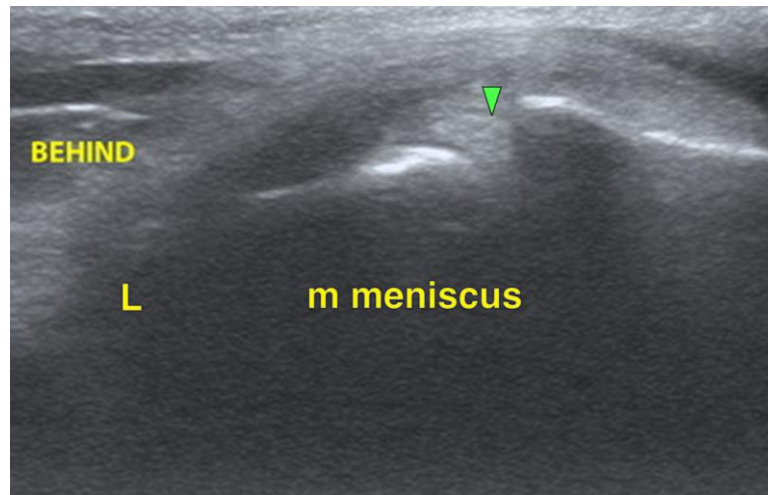
Dr. Simon

## INVOICE

74677

## DATE

4-20-26



The information and recommendations provided are based on the images presented by the referring veterinarian. No evaluation can be communicated regarding pathology that was not visible in the image/video clips provided.

Thank you for this referral. If the clinical or image interpretation does not parallel your findings or if I can be of any further assistance please contact me.

Nele Eley (Ondreka), DVM, Dr. med. vet., DipECVDI  
European Specialist in Veterinary Diagnostic Imaging, Cert. Radiology,  
Senior lecturer University of Giessen/Germany, Veterinary Faculty, Department of Radiology.  
[info@sonopath.com](mailto:info@sonopath.com)