



PATIENT

Zoe Greenspan

PRESENTING CLINICAL SIGNS

Chronic history of coughing , sneezing with discharge , on Heart medication Vetmedine for long time

SPECIES

Canine

Abnormal PE/Chem/CBC/UA Results: periodontal disease grade 4/4 , nasal discharge , cloudy eyes , submandibular LN swollen , heart murmur grade 4/6 , distended abdomen , bilateral patellar luxation ,, moderate muscle atrophy of both thighs , general weakness specially the hind end blood work indicated elevated liver enzymes , pancreatitis azotemia , mild anemia , mild hypercalcemia

BREED

Chihuahua

RADIOGRAPHIC STUDY OF THE THORAX

Right/left lateral and ventrodorsal views of the thorax and ventrodorsal view of the abdomen totaling 4 images available for review.

SEX

Female Spayed

Thoracic read requested.

RADIOGRAPHIC FINDINGS

T9/10 presents mild spondylosis deformans.

AGE

15 Years

The degree of pulmonary inflation is fair. No significant bronchopulmonary changes are seen.

INTERPRETED BY

Nele Eley, DVM
Dr. med. Vet. DipECVDI

The cervical trachea presents collapse level with and cranial to the thoracic inlet on the left lateral view. The degree of collapse is less pronounced on the right lateral view. No concurrent bronchial collapse is seen.

There is mild generalized cardiomegaly which appears to accentuate the left ventricle and left atrium with mild left atrial tenting and mild basico-apical enlargement of the cardiac silhouette, which is associated with mild tracheal elevation and a vertebral heart score of 12.1.

HOSPITAL NAME

Lakeshore Woods
Animal Hospital

There is no evidence of abnormal mediastinal widening.

Moderate generalized hepatomegaly with slightly rounded lobar margins is noted.

RADIOGRAPHIC DIAGNOSIS

REFERRING VET

Dr. Sam Masoud

- Dynamic tracheal disease.
- Mild left sided cardiomegaly with no evidence of congestive cardiac failure.
- Normal age related lung and bronchial tree.
- Moderate generalized hepatomegaly
- Spondylosis deformans T9/10 – incidental.

INVOICE

57921

INTERPRETATION OF THE FINDINGS & FURTHER RECOMMENDATIONS

DATE

4-20-23

The radiographic study reveals evidence of dynamic tracheal disease which appears to accentuate the cervical trachea. There also is mild left sided cardiomegaly with no evidence of congestive cardiac failure or volume overload. Myxomatous mitral valve degeneration with mitral valve regurgitation is the most common underlying cause of the pertinent radiographic presentation.



PATIENT

Zoe Greenspan

Differential diagnosis for the hepatomegaly includes vacuolar, metabolic, endocrine hepatopathy and less likely diffuse infiltrative disease and hepatitis. Correlation with the laboratory values recommended.

SPECIES

Canine

A full cardiac echo could be considered to further define the degree and significance of the radiographic changes.

Further workup of the tracheal collapse would require endoscopy.

BREED

Chihuahua

SEX

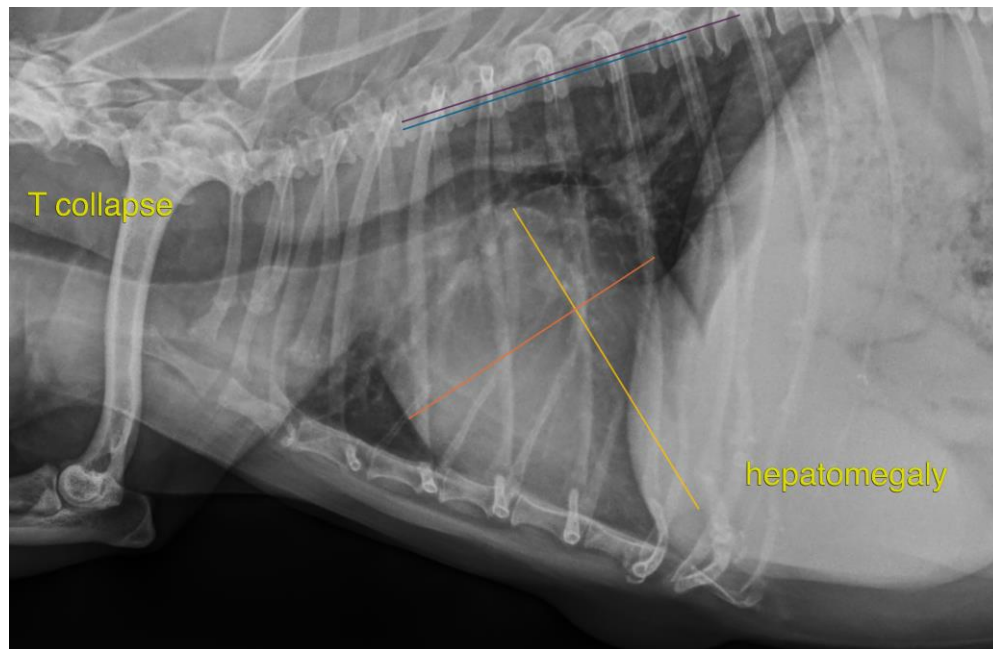
Female Spayed

AGE

15 Years

INTERPRETED BY

Nele Eley, DVM
Dr. med. Vet. DipECVDI



HOSPITAL NAME

Lakeshore Woods
Animal Hospital

The information and recommendations provided are based on the images presented by the referring veterinarian/sonographer. No evaluation can be communicated regarding pathology that was not visible in the image/video clips provided.

Thank you for this referral. If the clinical or image interpretation does not parallel your findings or if I can be of any further assistance please contact me.

REFERRING VET

Dr. Sam Masoud

Nele Eley, DVM, Dr. med. vet., DipECVDI
European Specialist in Veterinary Diagnostic Imaging, Cert. Radiology,
Senior lecturer University of Giessen, Germany, Veterinary Faculty, Department of Radiology
Nele.Eley@sonopath.com

INVOICE

57921

DATE

4-20-23