



PATIENT PRESENTING CLINICAL SIGNS

Brady Stofft Left sided facial paralysis.
Abnormal PE/Chem/CBC/UA Results: sedated by rDVM prior to CT

SPECIES COMPUTED TOMOGRAPHIC STUDY OF THE HEAD

Canine Plain and post-contrast studies available for review.

COMPUTED TOMOGRAPHIC FINDINGS

BREED Hound X
The brain presents no deviation from normal anatomy and symmetry. The grey and white matter distinction and the neuroparenchymal attenuation are as expected. The distribution of contrast enhancement is within normal limits throughout the parenchyma and meninges. The ventricular system is non-dilated and within the limits of the expected volume and symmetry.

SEX Neutered Male
Thin and smoothly folded conchae and turbinates with even smooth mucosal lining. The osseous lining of the nasal cavities is intact.

Both temporomandibular joints present congruent joint spaces with even subchondral bone surfaces and are considered within normal limits.

AGE 5 Years 5 Months
Both tympanic bullae are aerated, the mucosal lining is not seen, the bony wall is smooth and thin. The external auditory meatuses present within normal limits. The middle and inner ear present within normal limits.

INTERPRETED BY No evidence of structural abnormality is seen in the region of the palpebral fissures.

Nele Eley (Ondreka),
DVM Dr. med. vet.,
DipECVDI
The submandibular and medial retropharyngeal lymph nodes are small and elongated with a normal short-to-long-axis-ratio is < 0.5, the attenuation and contrast enhancement pattern is uniform.

The salivary glands present within normal limits.

HOSPITAL NAME The visible dentition within normal limits.

Mobile Pet Imaging **COMPUTED TOMOGRAPHIC DIAGNOSIS**

- Normal CT findings of the brain, middle and inner ear

REFERRING VET INTERPRETATION OF FINDINGS & FURTHER RECOMMENDATIONS

Dr. Meaux
INVOICE 46837
The CT study reveals no evidence of structural abnormality of the brain, inner ear within the pathways of the facial nerves, or within the middle ear. The negative CT findings support the potential of idiopathic facial neuropathy, which is the most common underlying cause of clinical facial paresis or paralysis in dogs. Complementary CSF analysis could be considered in order to rule out inflammatory infectious and other non-structural brain pathology.

DATE

3/20/23



PATIENT

Brady Stofft

SPECIES

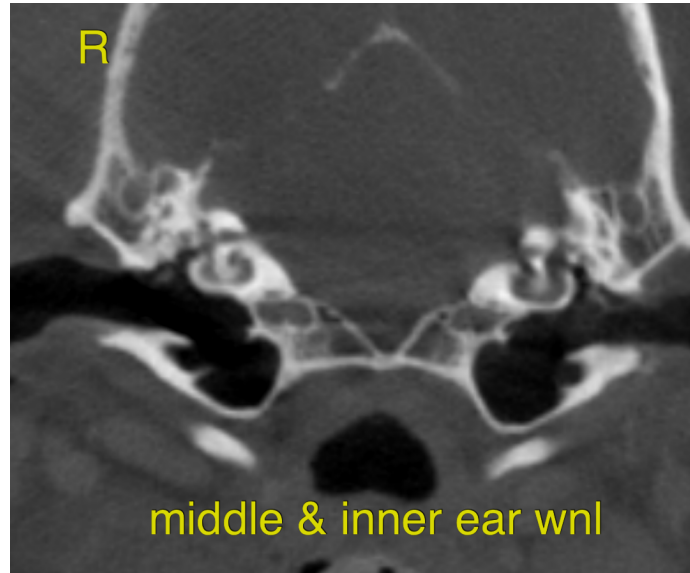
Canine

BREED

Hound X

SEX

Neutered Male



AGE

5 Years 5 Months

The information and recommendations provided are based on the images presented by the referring veterinarian. No evaluation can be communicated regarding pathology that was not visible in the image/video clips provided.

Thank you for this referral. If the clinical or image interpretation does not parallel your findings or if I can be of any further assistance please contact me.

INTERPRETED BY

Nele Eley (Ondreka),
DVM Dr. med. vet.,
DipECVDI

Nele Eley (Ondreka), DVM, Dr. med. vet., DipECVDI
European Specialist in Veterinary Diagnostic Imaging, Cert. Radiology,
Senior lecturer University of Giessen/Germany, Veterinary Faculty, Department of Radiology.
Nele.Eley@sonopath.com

HOSPITAL NAME

Mobile Pet Imaging

REFERRING VET

Dr. Meaux

INVOICE

46837

DATE

3/20/23