



**PATIENT**

Baxter SPCA SB  
476521

**PRESENTING CLINICAL SIGNS**

Injury to the left knee Dec 2021. Owner passed away and SPCA took over the care of this dog.  
Abnormal PE/Chem/CBC/UA Results: Positive Cranial drawer sign, CTT, medial bitress left stifle. TTA today

**SPECIES**

Canine

**ULTRASONOGRAPHIC FINDINGS**

**Left Stifle**

Moderate effusion is noted within the left stifle joint. There is moderate to severe swelling of the stifle joint synovium. A large amount of periarticular osteophytes are seen. The cranial cruciate ligament presents as an echogenic stump at the intercondylar eminence of the tibia. The lateral meniscus is situ and within normal limits. The medial meniscal tissue is disrupted, heterogeneous, and prolapsing beyond the osseous margins of the distal femur and proximal tibia. Extensive medial collateral ligament thickening is seen.

**BREED**

Pitbull Mix

**SEX**

MN

**ULTRASONOGRAPHIC DIAGNOSIS**

- Moderate to severe left stifle osteoarthritis with full cranial cruciate ligament rupture and medial meniscal injury.

**AGE**

5 Years, 1 Month

**INTERPRETATION OF THE FINDINGS & FURTHER RECOMMENDATIONS**

The ultrasonographic findings support the presence of complete rupture of the left cranial cruciate ligament with secondary medial meniscal tear and prolapse. Surgical intervention is recommended in order to address the biomechanical instability and revise the medial meniscus in order to prevent further damage to the joint.

**INTERPRETED BY**

Nele Eley, DVM  
Dr. med. Vet. DipECVDI

**HOSPITAL NAME**

Westview Veterinary  
Hospital

**REFERRING VET**

Dr Brian J Barnes

**INVOICE**

57914

**DATE**

4-20-23



**PATIENT**

Baxter SPCA SB  
476521

**SPECIES**

Canine

**BREED**

Pitbull Mix

**SEX**

MN

**AGE**

5 Years, 1 Month

**INTERPRETED BY**

Nele Eley, DVM  
Dr. med. Vet. DipECVDI

**HOSPITAL NAME**

Westview Veterinary  
Hospital

**REFERRING VET**

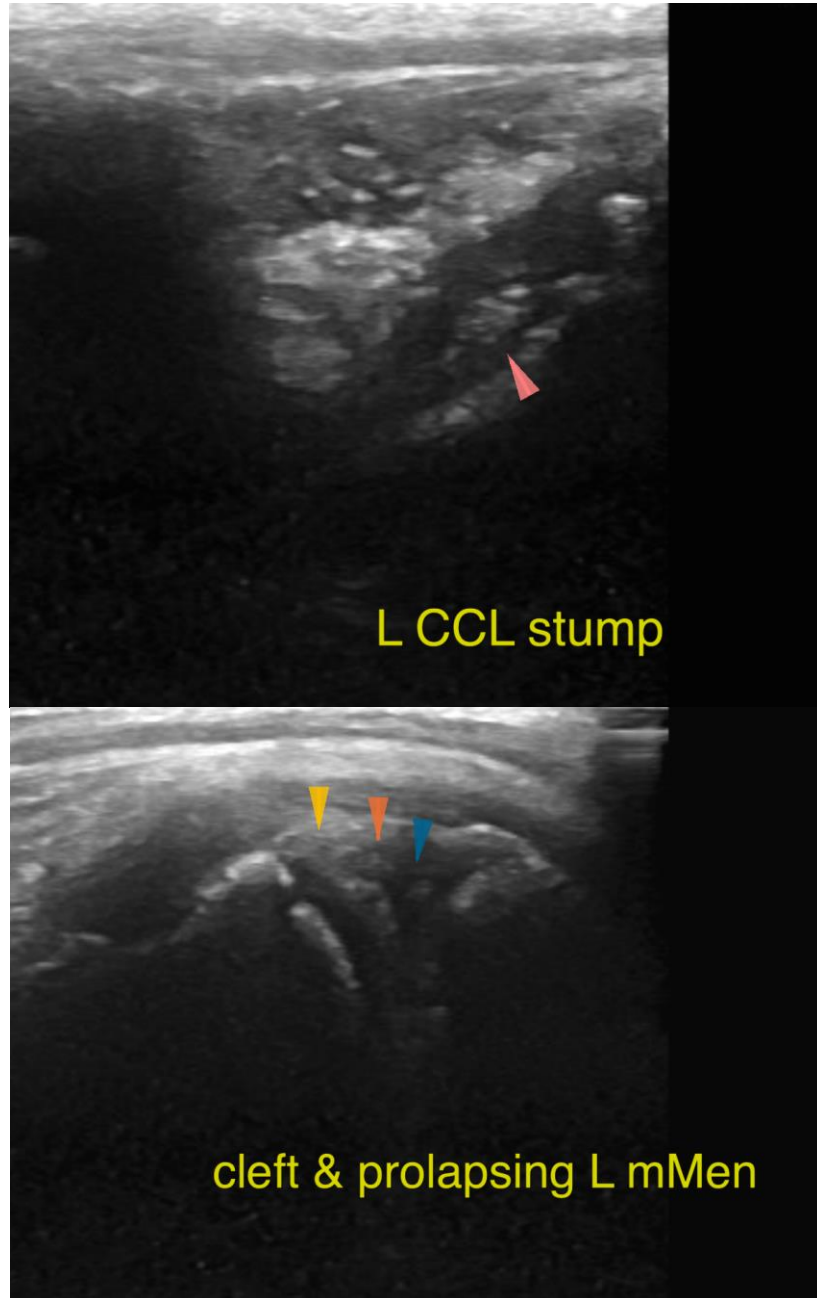
Dr Brian J Barnes

**INVOICE**

57914

**DATE**

4-20-23





**PATIENT**

Baxter SPCA SB  
476521

**SPECIES**

Canine

**BREED**

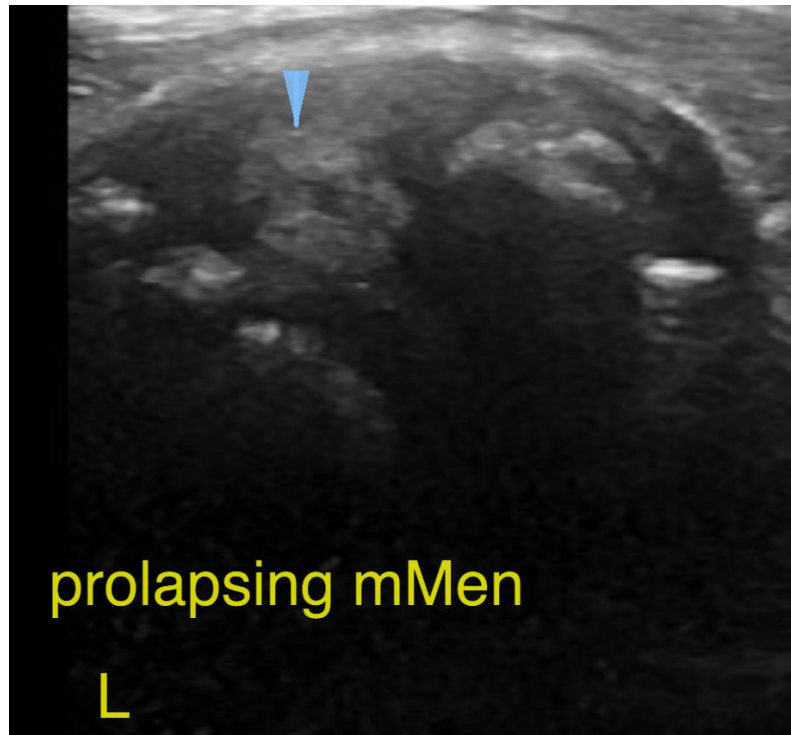
Pitbull Mix

**SEX**

MN

**AGE**

5 Years, 1 Month



**INTERPRETED BY**

Nele Eley, DVM  
Dr. med. Vet. DipECVDI

**HOSPITAL NAME**

Westview Veterinary  
Hospital

**REFERRING VET**

Dr Brian J Barnes

**INVOICE**

57914

**DATE**

4-20-23

The information and recommendations provided are based on the images presented by the referring veterinarian/sonographer. No evaluation can be communicated regarding pathology that was not visible in the image/video clips provided.

Thank you for this referral. If the clinical or image interpretation does not parallel your findings or if I can be of any further assistance please contact me.

**Nele Eley**, DVM, Dr. med. vet., DipECVDI  
European Specialist in Veterinary Diagnostic Imaging, Cert. Radiology,  
Senior lecturer University of Giessen, Germany, Veterinary Faculty, Department of Radiology  
Nele.Eley@sonopath.com