



PATIENT PRESENTING CLINICAL SIGNS

Pixie Lemigova Rule out retrobulbar mass.

COMPUTED TOMOGRAPHIC STUDY OF THE HEAD

SPECIES Plain and post contrast studies available for review.

Feline

COMPUTED TOMOGRAPHIC FINDINGS

BREED

Siamese Mix

The brain presents no deviation from normal anatomy and symmetry. The grey and white matter distinction and the neuroparenchymal attenuation are as expected. The distribution of contrast enhancement is within normal limits throughout the parenchyma and meninges. The ventricular system is non-dilated and within the limits of the expected volume and symmetry.

SEX

Spayed Female

Thin and smoothly folded conchae and turbinates with even smooth mucosal lining. The osseous lining of the nasal cavities is intact.

Both temporomandibular joints present congruent joint spaces with even subchondral bone surfaces and are considered within normal limits.

AGE

3 Years

Both tympanic bullae are aerated, the mucosal lining is not seen, the bony wall is smooth and thin. The external auditory meatuses present within normal limits.

Mild right sided exophthalmos appears to be present. There is diffuse swelling of the periocular and periorbital soft tissues circumferential to the anterior aspect of the right eye with diffusely increased contrast enhancement. No evidence of a retrobulbar mass is seen.

INTERPRETED BY

Nele Eley (Ondreka),
DVM Dr. med. vet.,
DipECVDI

The right medial retropharyngeal lymph node presents mild symmetric enlargement.

The salivary glands present within normal limits.

HOSPITAL NAME

Mobile Pet Imaging

COMPUTED TOMOGRAPHIC DIAGNOSIS

- Right sided periocular soft tissue swelling with increased contrast enhancement.
- Right medial retropharyngeal lymphadenomegaly - mild.

INTERPRETATION OF FINDINGS & FURTHER RECOMMENDATIONS

REFERRING VET

Meaux

Differential diagnosis includes diffuse and severe conjunctivitis, periorbital inflammation, idiopathic sclerosing orbital pseudotumor, and feline restrictive orbital sarcoma.

The lymph node changes are suggestive for reactive hyperplasia. However, early metastatic disease cannot be ruled out entirely.

INVOICE

51649

Further definition by means of sampling of the periocular tissues and fine needle aspiration of the lymph node is recommended.

DATE

4-20-22



PATIENT

Pixie Lemigova

SPECIES

Feline

BREED

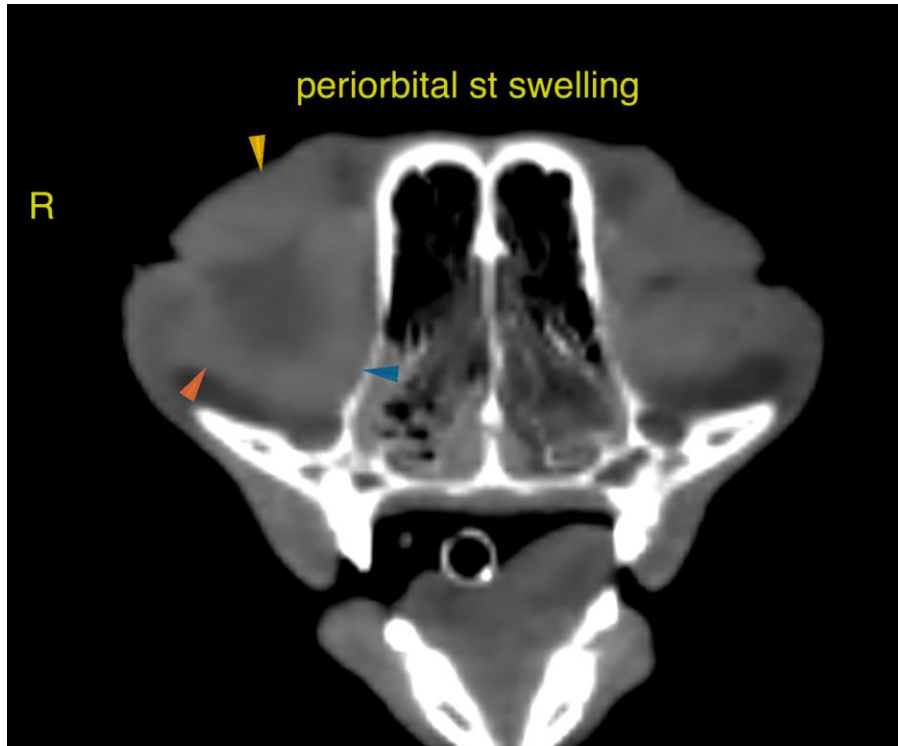
Siamese Mix

SEX

Spayed Female

AGE

3 Years



INTERPRETED BY

Nele Eley (Ondreka),
DVM Dr. med. vet.,
DipECVDI

The information and recommendations provided are based on the images presented by the referring veterinarian. No evaluation can be communicated regarding pathology that was not visible in the image/video clips provided.

Thank you for this referral. If the clinical or image interpretation does not parallel your findings or if I can be of any further assistance please contact me.

HOSPITAL NAME

Mobile Pet Imaging

Nele Eley (Ondreka), DVM, Dr. med. vet., DipECVDI
European Specialist in Veterinary Diagnostic Imaging, Cert. Radiology,
Senior lecturer University of Giessen/Germany, Veterinary Faculty, Department of Radiology.
Nele.Eley@sonopath.com

REFERRING VET

Meaux

INVOICE

51649

DATE

4-20-22