



PATIENT

Kali Rini

PRESENTING CLINICAL SIGNS

Intermittent vomiting and hyporexia for 10 days. No vomiting last 3 days. 1 episode of diarrhea, otherwise normal stool. Exam normal, blood work pending

SPECIES

Canine

RADIOGRAPHIC STUDY OF THE ABDOMEN

Right/left lateral and ventrodorsal views totaling 3 images available for review.

BREED

Cavapoo

RADIOGRAPHIC FINDINGS

The abdominal serosal detail is maintained.

SEX

Female

The stomach is post-prandial. A mild amount of gravel is seen within the stomach and descending duodenum contains a mild amount of gas.

The small intestinal loops are evenly distributed throughout out the mid abdomen. No evidence of abnormal dilation, plication, or radiopaque foreign material is seen.

The cecum and colon contain a mild amount of gas and fecal matter.

AGE

6 Months

RADIOGRAPHIC DIAGNOSIS

- Post-prandial stomach versus delayed gastric emptying.

INTERPRETED BY

Nele Eley, DVM
Dr. med. Vet. DipECVDI

INTERPRETATION OF THE FINDINGS & FURTHER RECOMMENDATIONS

The radiographic study reveals no direct signs of mechanical ileus. Consider functional ileus a likely potential based on the radiographic findings. The gastric gravel sign may be due to delayed gastric emptying. However, the findings may also reflect a post-prandial state. Consider further definition by means of abdominal ultrasound in case of persisting or deteriorating/recurring clinical signs.

HOSPITAL NAME

Four Corners
Veterinary Practice

REFERRING VET

Gregory Roccaro

INVOICE

51645

DATE

4-20-22



PATIENT

Kali Rini

SPECIES

Canine

BREED

Cavapoo

SEX

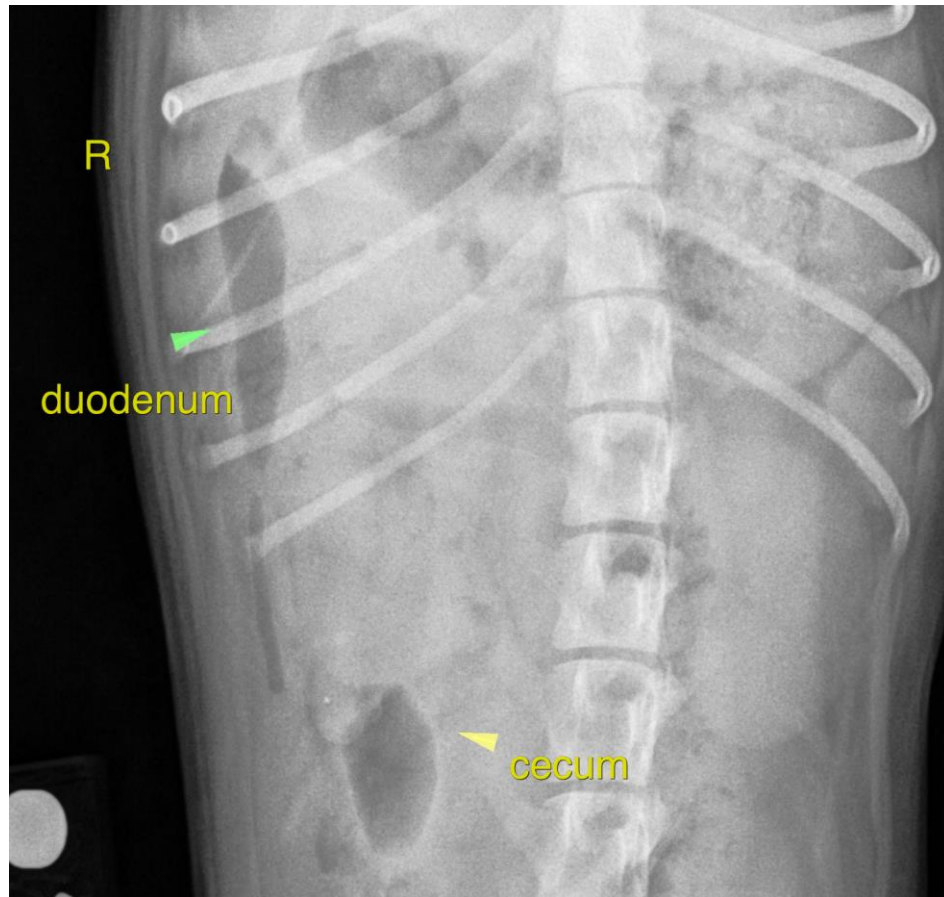
Female

AGE

6 Months

INTERPRETED BY

Nele Eley, DVM
Dr. med. Vet. DipECVDI



HOSPITAL NAME

Four Corners
Veterinary Practice

REFERRING VET

Gregory Roccaro

INVOICE

51645

DATE

4-20-22

The information and recommendations provided are based on the images presented by the referring veterinarian/sonographer. No evaluation can be communicated regarding pathology that was not visible in the image/video clips provided.

Thank you for this referral. If the clinical or image interpretation does not parallel your findings or if I can be of any further assistance please contact me.

Nele Eley, DVM, Dr. med. vet., DipECVDI
European Specialist in Veterinary Diagnostic Imaging, Cert. Radiology,
Senior lecturer University of Giessen, Germany, Veterinary Faculty, Department of Radiology
Nele.Eley@sonopath.com