



PATIENT

Budders Angus

SPECIES

Canine

BREED

Bullmastiff

SEX

M

AGE

3 Years, 10 Months

INTERPRETED BY

Nele Eley, DVM
Dr. med. Vet. DipECVDI

HOSPITAL NAME

Westview Veterinary
Hospital

REFERRING VET

Dr. Brian Barnes

INVOICE

51641

DATE

4-20-22

PRESENTING CLINICAL SIGNS

Bilateral stifle effusions. Favoring right stifle more. Has a partial tear to the right CCI
Abnormal PE/Chem/CBC/UA Results: Partial Cr drawer and CTT. Medial buttress sign on the right knee.

ULTRASONOGRAPHIC FINDINGS

Right Stifle

A moderate amount of anechoic effusion is noted in the supra- and infra- patellar recesses of the right stifle joint.

The cranial cruciate ligament is continuous, yet it appears to be thickened with ill-defined margins and nonuniform internal echoarchitecture.

The lateral and medial menisci are in situ with smoothly delineated surface and uniform internal echoarchitecture.

A moderate amount of swelling of the synovium and a moderate amount of periarticular osteophytes are noted.

ULTRASONOGRAPHIC DIAGNOSIS

- Moderate right stifle osteoarthritis with cranial cruciate ligament pathology - no evidence of concurrent meniscopathy.

INTERPRETATION OF THE FINDINGS & FURTHER RECOMMENDATIONS

The ultrasonographic findings are compatible with partial rupture of the right cranial cruciate ligament. Moderate osteoarthritis findings with marked synovialitis are seen as well. Surgical intervention has been performed in order to address the biomechanical instability of the joint and prevent further damage to the articular structures such as the menisci.



PATIENT

Budders Angus

SPECIES

Canine

BREED

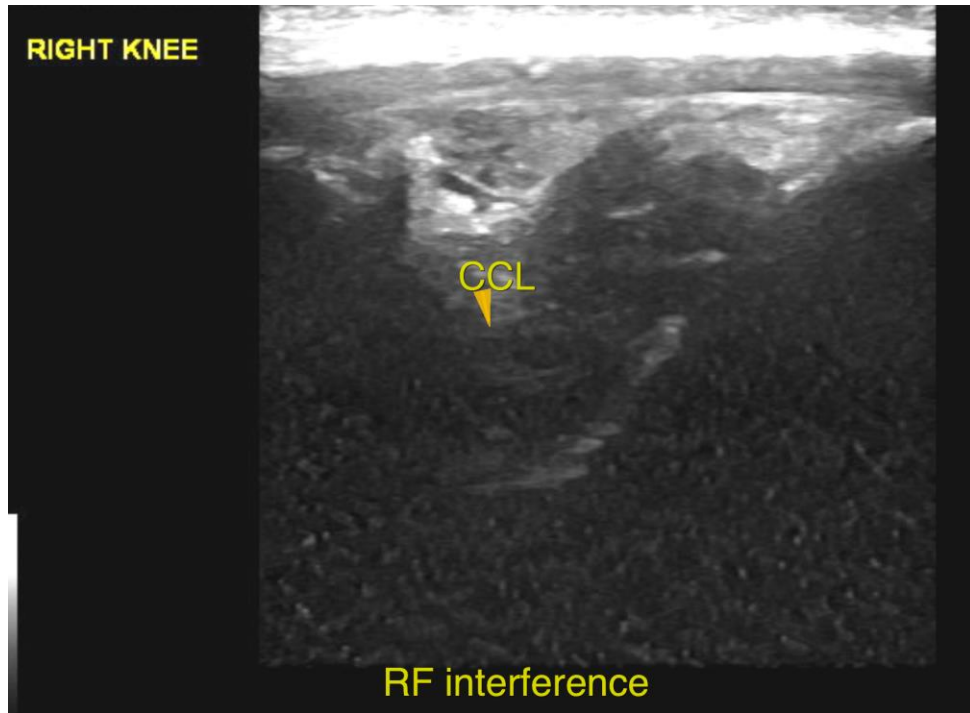
Bullmastiff

SEX

M

AGE

3 Years, 10 Months



INTERPRETED BY

Nele Eley, DVM
Dr. med. Vet. DipECVDI

The information and recommendations provided are based on the images presented by the referring veterinarian/sonographer. No evaluation can be communicated regarding pathology that was not visible in the image/video clips provided.

Thank you for this referral. If the clinical or image interpretation does not parallel your findings or if I can be of any further assistance please contact me.

HOSPITAL NAME

Westview Veterinary
Hospital

Nele Eley, DVM, Dr. med. vet., DipECVDI
European Specialist in Veterinary Diagnostic Imaging, Cert. Radiology,
Senior lecturer University of Giessen, Germany, Veterinary Faculty, Department of Radiology
Nele.Eley@sonopath.com

REFERRING VET

Dr. Brian Barnes

INVOICE

51641

DATE

4-20-22