



PATIENT PRESENTING CLINICAL SIGNS

Felix Vucina acute Vomiting since Friday just bile , not eating , lethargic, hiding , not vaccinated since he was kitten, total indoor , no Hx. of eating foreign objects or any sickness.

SPECIES Abnormal PE/Chem/CBC/UA Results: Moderate abdominal distension and pain during palpation , dehydration 7% , bloodwork : moderate azotemia , hyperglycemia , elevated ALT , mild hyponatremia , fPI elevated , CBC: mild stress leukogram and dehydration, Hospitalized for IV fluid therapy and supportive care for 48 hours, Suspected FB , Pancreatitis , kidney disease (SDMA and UPC ration was sent for confirmation)

Feline

BREED RADIOGRAPHIC STUDY OF THE THORAX & ABDOMEN

DSH Right/left lateral and ventrodorsal whole body views totaling 3 images available for review.

RADIOGRAPHIC FINDINGS

SEX Abdomen

Male Neutered The small intestine is bunched together in the ventral right abdomen. No evidence of reduced serosal detail or dilation is seen. However, a segmental eccentric gas pattern of the small intestine is noted and both the stomach as well as the descending duodenum are dilated with gas.

AGE

11 Years The liver, splenic head, kidneys, and urinary bladder present within normal limits except for distension of the urinary bladder.

INTERPRETED BY

Nele Eley, DVM
Dr. med. Vet. DipECVDI

The large intestine contains a moderate amount of highly inspissated fecal matter.

Mineralization of the intervertebral discs L6/7 & L7/S1 is seen.

Thorax

HOSPITAL NAME

Lakeshore Woods
Animal Hospital

The cardiac silhouette is upright and thin. No specific chamber enlargement is noted. There is no evidence of atrial enlargement. The pulmonary vasculature is thin.

A mild generalized bronchointerstitial pattern is noted which may be within age related normal limits.

REFERRING VET

Dr. Sam Masoud

RADIOGRAPHIC DIAGNOSIS

- Suspect plication of the small intestine with small intestinal ileus.
- Dehydration with large intestinal constipation.
- Microcardia and hypoperfusion of the lung.

INVOICE

57576

INTERPRETATION OF THE FINDINGS & FURTHER RECOMMENDATIONS

DATE

4-2-23

The radiographic findings suggest potential for linear small intestinal foreign material. Other causes of plication would include severe enteritis and infiltrative disease. Further definition by means of abdominal ultrasound is strongly recommended if not performed already. Rehydrating and stabilizing the patient should be performed in the meantime.



PATIENT

Felix Vucina

SPECIES

Feline

BREED

DSH

SEX

Male Neutered

AGE

11 Years

INTERPRETED BY

Nele Eley, DVM
Dr. med. Vet. DipECVDI

HOSPITAL NAME

Lakeshore Woods
Animal Hospital

REFERRING VET

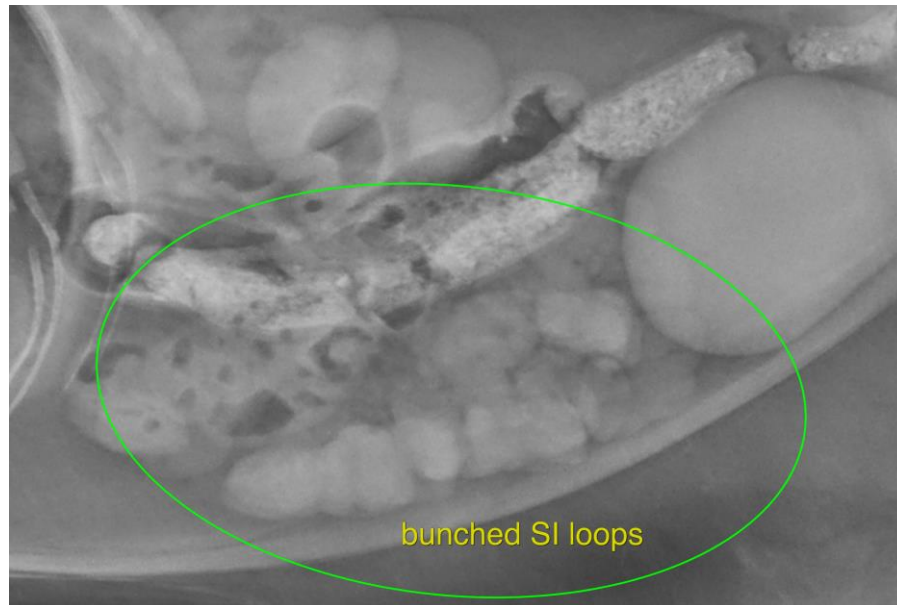
Dr. Sam Masoud

INVOICE

57576

DATE

4-2-23



The information and recommendations provided are based on the images presented by the referring veterinarian/sonographer. No evaluation can be communicated regarding pathology that was not visible in the image/video clips provided.

Thank you for this referral. If the clinical or image interpretation does not parallel your findings or if I can be of any further assistance please contact me.

Nele Eley, DVM, Dr. med. vet., DipECVDI
European Specialist in Veterinary Diagnostic Imaging, Cert. Radiology,
Senior lecturer University of Giessen, Germany, Veterinary Faculty, Department of Radiology
Nele.Eley@sonopath.com