



**PATIENT**

Otis Roudebush

**PRESENTING CLINICAL SIGNS**

Limping on right hind.

**SPECIES**

Canine

**RADIOGRAPHIC STUDY OF THE RIGHT STIFLE**

Mediolateral views of the right stifle and ventrodorsal view of the pelvis including craniocaudal view of the stifles totaling 3 images available for review.

**BREED**

Mastiff Mix

**RADIOGRAPHIC FINDINGS**

Mild cranial thrust of the tibia is noted.

**SEX**

Male Neutered

There is moderate to severe articular swelling of the right stifle joint.

A large amount of periarticular osteophytes are seen accentuating the femoral trochlea, distal pole of the patella, cranial margin of the tibial plateau, and the fabellae. New bone formation is noted in the caudal margin of the tibial plateau.

The craniocaudal view shows atrophy of the right hind limb musculature.

**AGE**

3 Years

**RADIOGRAPHIC DIAGNOSIS**

- Moderate to severe right stifle osteoarthritis with radiographic evidence of cranial cruciate ligament failure.
- Disuse atrophy of the right hind limb musculature.

**INTERPRETED BY**

Nele Eley, DVM  
Dr. med. Vet. DipECVDI

**INTERPRETATION OF THE FINDINGS & FURTHER RECOMMENDATIONS**

The radiographic findings are compatible with loss of the biomechanical function of the right cranial cruciate ligament. Elongation, partial rupture, and complete rupture are potential underlying causes. Full rupture appears most likely with the significant cranial thrust of the tibia. The arthropathy is accompanied by moderate to severe osteoarthritic changes and signs of chronic disuse of the right hind limb. Consider surgical intervention in order to address the biomechanical instability and prevent further damage to the articular structures including the menisci.

**HOSPITAL NAME**

St. Catherine's Animal  
Hospital

**REFERRING VET**

Dr. Boctor

**INVOICE**

57898

**DATE**

4-19-23



**PATIENT**

Otis Roudebush

**SPECIES**

Canine

**BREED**

Mastiff Mix

**SEX**

Male Neutered

**AGE**

3 Years

**INTERPRETED BY**

Nele Eley, DVM  
Dr. med. Vet. DipECVDI

**HOSPITAL NAME**

St. Catherine's Animal  
Hospital

**REFERRING VET**

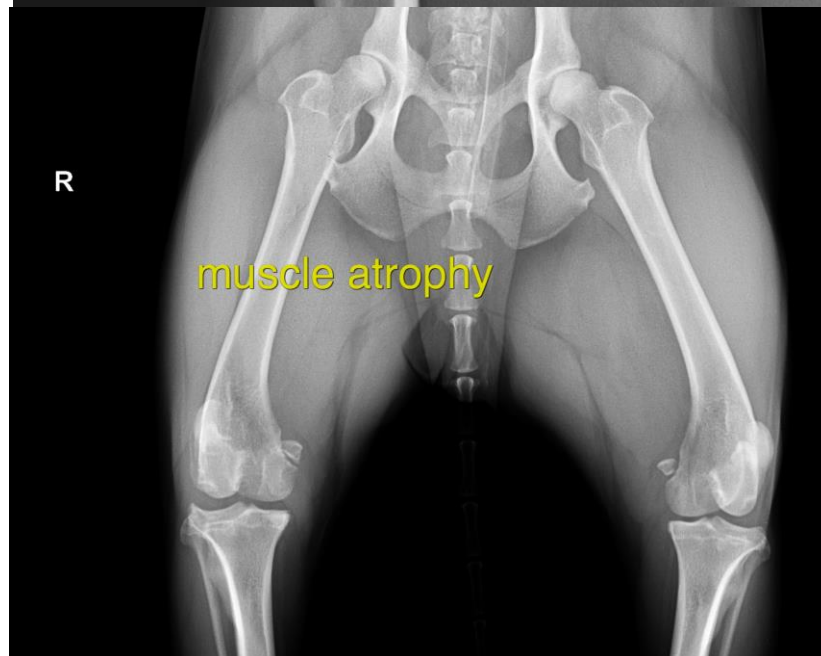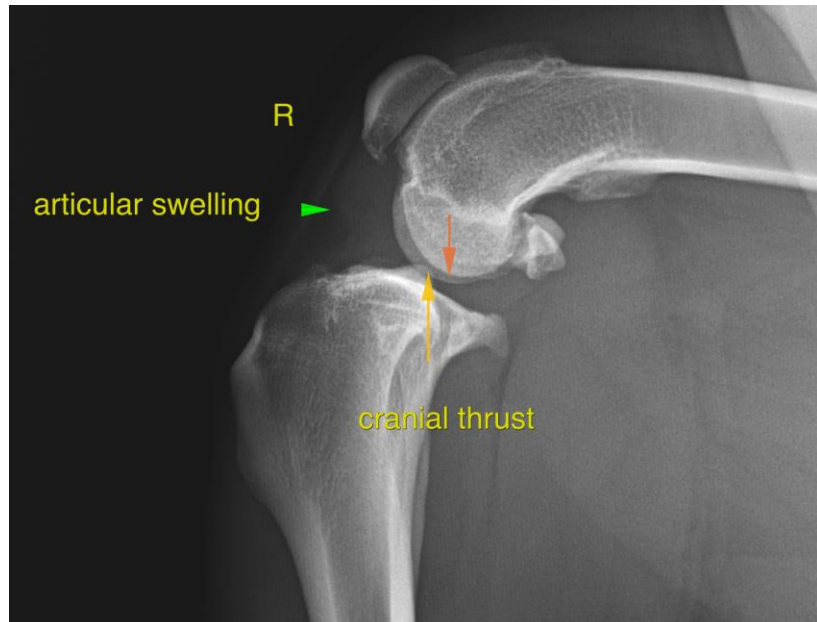
Dr. Boctor

**INVOICE**

57898

**DATE**

4-19-23





**PATIENT**

Otis Roudebush

The information and recommendations provided are based on the images presented by the referring veterinarian/sonographer. No evaluation can be communicated regarding pathology that was not visible in the image/video clips provided.

Thank you for this referral. If the clinical or image interpretation does not parallel your findings or if I can be of any further assistance please contact me.

**SPECIES**

Canine

**Nele Eley**, DVM, Dr. med. vet., DipECVDI  
European Specialist in Veterinary Diagnostic Imaging, Cert. Radiology,  
Senior lecturer University of Giessen, Germany, Veterinary Faculty, Department of Radiology  
Nele.Eley@sonopath.com

**BREED**

Mastiff Mix

**SEX**

Male Neutered

**AGE**

3 Years

**INTERPRETED BY**

Nele Eley, DVM  
Dr. med. Vet. DipECVDI

**HOSPITAL NAME**

St. Catherine's Animal  
Hospital

**REFERRING VET**

Dr. Boctor

**INVOICE**

57898

**DATE**

4-19-23