

**PATIENT**

Baxter Duncan

PRESENTING CLINICAL SIGNS

Patient presented for suborbital swelling that has been present for 1 month. No improvement with antibiotics. Primary vet extracted 208 1 month ago due to suspected tooth root abscess.

SPECIES

Canine

COMPUTED TOMOGRAPHIC STUDY OF THE HEAD

Plain study available for review.

BREED

Alaskan Malamute

COMPUTED TOMOGRAPHIC FINDINGS

Severe expansion of the left nasolacrimal duct with moth eaten osteolysis is seen starting from the orbita and extending rostrally up to the level of the triadan 207. Lateral opening of the expanded nasolacrimal duct with a large adjacent soft tissue mass paralleling the left maxilla of approximately 4.5 cm length and 2.0 cm diameter is seen. A soft tissue component of the mass is seen within the rostroventral portion of the left orbita.

SEX

MN

A remnant of the mesial palatinal root of the triadan 208 is present.

Mild regional mucosal swelling is seen within the left nasal cavity.

AGE

5 Years

COMPUTED TOMOGRAPHIC DIAGNOSIS

- Osseous expansion and lysis of the left nasolacrimal duct with associated soft tissue mass.
- Concurrent regional left hand sided rhinitis.
- History of incomplete extraction of the triadan 208 with root remnant.

INTERPRETED BY

Nele Eley, DVM
Dr. med. Vet. DipECVDI

INTERPRETATION OF THE FINDINGS & FURTHER RECOMMENDATIONS

The CT study reveals severe expansion of the left nasolacrimal duct with a large soft tissue mass within and outside of the expanded duct. Differential diagnosis includes dacryops with regional osteitis and granulomatous cellulitis secondary to foreign material or nonforeign material related inflammation/infection of the nasolacrimal duct as well as soft tissue neoplasia with secondary aggressive bone lysis. Tissue sampling is recommended for further definition. Consider FNA of the regional lymph nodes and thoracic staging as well.

HOSPITAL NAME

Animal Dental Clinic

REFERRING VET

Donald Otten

INVOICE

57902

DATE

4-19-23



PATIENT

Baxter Duncan

SPECIES

Canine

BREED

Alaskan Malamute

SEX

MN

AGE

5 Years

INTERPRETED BY

Nele Eley, DVM
Dr. med. Vet. DipECVDI

HOSPITAL NAME

Animal Dental Clinic

REFERRING VET

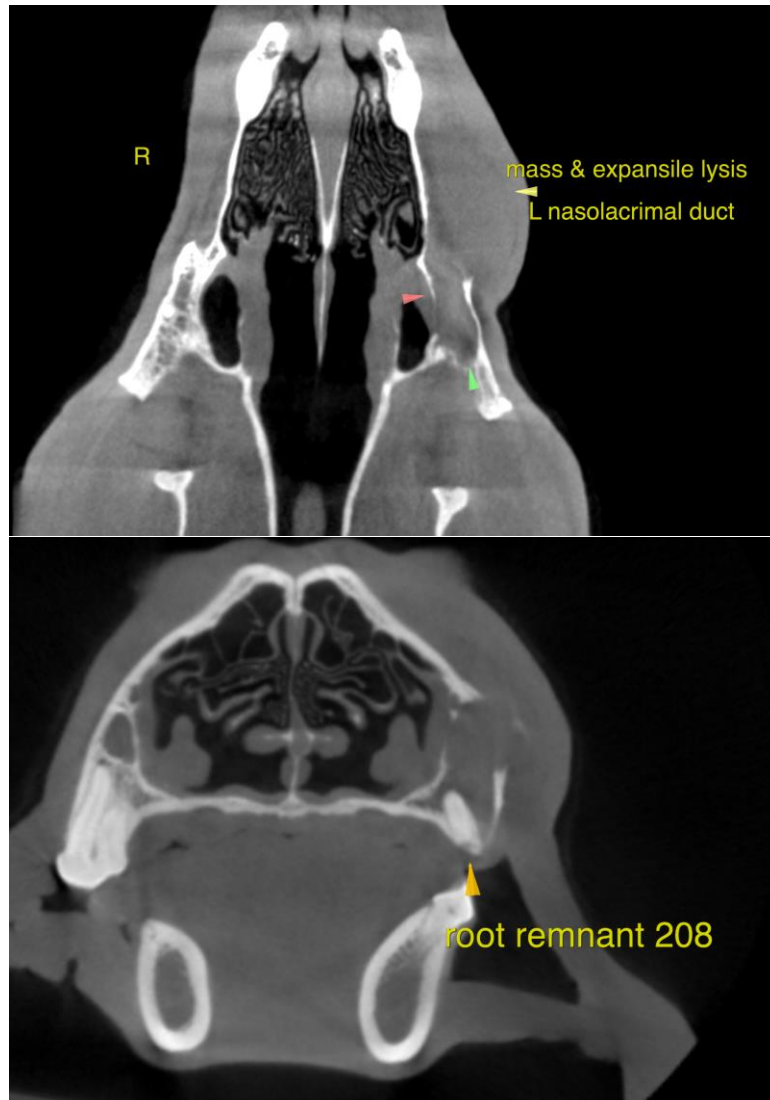
Donald Otten

INVOICE

57902

DATE

4-19-23



The information and recommendations provided are based on the images presented by the referring veterinarian/sonographer. No evaluation can be communicated regarding pathology that was not visible in the image/video clips provided.

Thank you for this referral. If the clinical or image interpretation does not parallel your findings or if I can be of any further assistance please contact me.

Nele Eley, DVM, Dr. med. vet., DipECVDI
European Specialist in Veterinary Diagnostic Imaging, Cert. Radiology,
Senior lecturer University of Giessen, Germany, Veterinary Faculty, Department of Radiology
Nele.Eley@sonopath.com