



**PATIENT PRESENTING CLINICAL SIGNS**

Jewel Norris Seizures: R/O Portosystemic Shunt

**COMPUTED TOMOGRAPHIC STUDY OF THE HEAD & ABDOMEN**

**SPECIES**

Plain and post contrast studies of the head and abdomen available for review.

Canine

**COMPUTED TOMOGRAPHIC FINDINGS**

**BREED**

**Head**

Australian Shepherd

The brain presents no deviation from normal anatomy and symmetry. The grey and white matter distinction and the neuroparenchymal attenuation are as expected. The distribution of contrast enhancement is within normal limits throughout the parenchyma and meninges. The ventricular system is non-dilated and within the limits of the expected volume and symmetry.

**SEX**

Female Intact

Thin and smoothly folded conchae and turbinates with even smooth mucosal lining. The osseous lining of the nasal cavities is intact.

**AGE**

7 Months

Both temporomandibular joints present congruent joint spaces with even subchondral bone surfaces and are considered within normal limits.

Both tympanic bullae are aerated, the mucosal lining is not seen, the bony wall is smooth and thin. The external auditory meatuses present within normal limits.

**INTERPRETED BY**

Nele Eley (Ondreka),  
DVM Dr. med. vet.,  
DipECVDI

The submandibular and medial retropharyngeal lymph nodes are small and elongated with a normal short-to-long-axis-ratio is < 0.5, the attenuation and contrast enhancement pattern is uniform.

The salivary glands present within normal limits.

The visible dentition is within normal limits.

**HOSPITAL NAME**

Mobile Pet Imaging  
CFL

**Abdomen**

The serosal fat presents normal attenuation behavior. There is no evidence of peritoneal effusion or peritonitis.

**REFERRING VET**

Borecky

Both kidneys present within normal limits for size, shape and organ architecture. After contrast administration a bilaterally symmetric and uniform nephro- and pyelogram is noted.

The adrenal glands are within normal limits for size, shape and organ architecture.

**INVOICE**

51616

Both liver and spleen present with normal shape, even surface, uniformly attenuating parenchyma and homogeneous contrast enhancement, unremarkable.

The portal vein presents a normal order of its tributary veins and intrahepatic branching. No abnormal vessel is noted inside and outside of the liver parenchyma.

**DATE**

4-19-22



**PATIENT** The pancreas is evenly contoured, the pancreatic parenchyma is homogeneous and presents uniform contrast enhancement.

Jewel Norris

The position, delineation, wall and content of the gastrointestinal tract are considered within normal limits throughout.

**SPECIES**

Canine

The bony and surrounding soft tissue structures reveal no abnormalities.

**COMPUTED TOMOGRAPHIC DIAGNOSIS**

- Structurally normal CT study of the brain and abdomen.

**BREED**

Australian Shepherd

**INTERPRETATION OF THE FINDINGS & FURTHER RECOMMENDATIONS**

No evidence of structural brain pathology is identified and there is no evidence of intra- or extra-hepatic portosystemic shunts.

**SEX**

Female Intact

Primary epilepsy appears to be one main differential diagnosis based on the negative CT findings and patient history. Complementary CSF analysis could be considered to rule out inflammatory/infectious and other brain pathology.

**AGE**

7 Months

No macroscopic vascular bypass of the liver was noted in the pre- and post-contrast studies of the abdomen. However, if the clinical signs are consistent with insufficiency of the liver, primary non-cirrhotic portal hypertension (microvascular dysplasia) or other diffuse parenchymal liver disease would still be a potential and should be ruled out by means of ultrasound guided or surgical liver biopsy.

**INTERPRETED BY**

Nele Eley (Ondreka),  
DVM Dr. med. vet.,  
DipECVDI

In general ultrasound guided Tru-cut biopsies of the liver may be performed with reasonably low potential for complications under the following conditions: platelet count  $> 50 \times 10^3/\mu\text{l}$ ,  $< 25\%$  prolongation of PT/PTT – less of deviation from normal values acceptable in presence of peritoneal effusion. The intensity of the post procedural patient monitoring needs to be tailored to the degree of deviation from normal reference ranges.

**HOSPITAL NAME**

Mobile Pet Imaging  
CFL

**REFERRING VET**

Borecky

**INVOICE**

51616

**DATE**

4-19-22



**PATIENT**

Jewel Norris

**SPECIES**

Canine

**BREED**

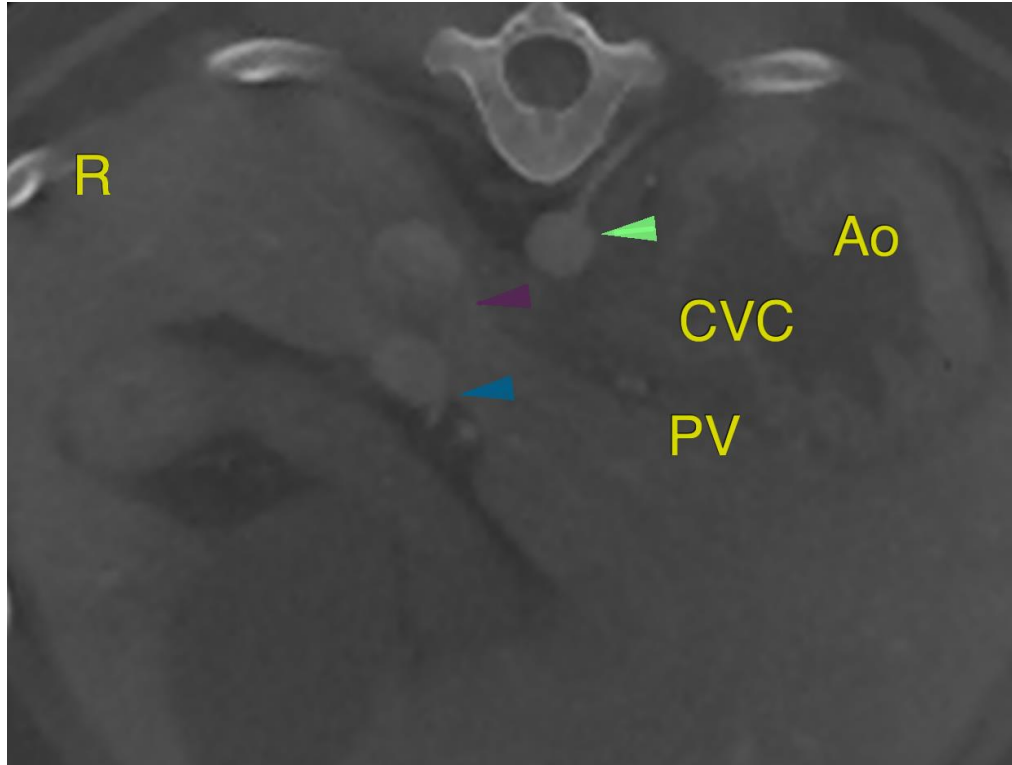
Australian Shepherd

**SEX**

Female Intact

**AGE**

7 Months



**INTERPRETED BY**

Nele Eley (Ondreka),  
DVM Dr. med. vet.,  
DipECVDI

The information and recommendations provided are based on the images presented by the referring veterinarian. No evaluation can be communicated regarding pathology that was not visible in the image/video clips provided.

Thank you for this referral. If the clinical or image interpretation does not parallel your findings or if I can be of any further assistance please contact me.

**HOSPITAL NAME**

Mobile Pet Imaging  
CFL

**Nele Eley (Ondreka)**, DVM, Dr. med. vet., DipECVDI  
European Specialist in Veterinary Diagnostic Imaging, Cert. Radiology,  
Senior lecturer University of Giessen/Germany, Veterinary Faculty, Department of Radiology.  
Nele.Eley@sonopath.com

**REFERRING VET**

Borecky

**INVOICE**

51616

**DATE**

4-19-22