



PATIENT PRESENTING CLINICAL SIGNS

Yeti Lachanse Right intermittent forelimb lameness - diagnosis open but not limited to elbow dysplasia, shoulder OCD, biceps tenosynovitis, shoulder subluxation, other soft tissue injury

SPECIES COMPUTED TOMOGRAPHIC STUDY OF THE SHOULDERS, ELBOWS, & CARPAL JOINTS

Canine Plain study available for review in soft tissue window only.

COMPUTED TOMOGRAPHIC FINDINGS

BREED Elbows

Labrador Retriever A 7 x 4mm sized elongated wedge shaped fragment is isolated from the tip of the right medial coronoid process. The base of the right medial coronoid process presents sclerosis. A 4mm width and 2.5mm deep subchondral bone defect is seen in the medial humeral condyle and surrounded by peripheral sclerosis. A large amount of periarticular osteophytes is seen.

SEX M A fissure line and radioulnar incisure incongruity are noted in the left elbow. There are several up to 2mm sized subchondral bone defects within the medial humeral condyle which are surrounded by peripheral sclerosis. Mild periarticular osteophytes are seen.

AGE Shoulder & Carpal Joints

1 Year The bilateral shoulder and carpal joints present within normal limits.

INTERPRETED BY There is no evidence of shoulder osteochondritis or biceps tenosynovitis.

Nele Eley, DVM
Dr. med. Vet. DipECVDI The carpal bones are in situ and intact.

HOSPITAL NAME COMPUTED TOMOGRAPHIC DIAGNOSIS

- Animal Health Partners
- Fragmentation of the medial coronoid process and osteochondritis of the medial humeral condyle in the right elbow with severe secondary right elbow osteoarthritis.
- Medial coronoid pathology with fissure and osteochondritis of the medial humeral condyle in the left elbow followed by mild secondary osteoarthritis.

- REFERRING VET** Normal shoulders
- Normal carpal joints.

Dr. Kim Murphy **INTERPRETATION OF THE FINDINGS & FURTHER RECOMMENDATIONS**

INVOICE The CT study reveals bilateral elbow dysplasia. Two primary lesions, medial coronoid disease, and osteochondritis of the medial humeral condyle are seen in both elbows. The findings are more pronounced in the right elbow where a large fragment is isolated from the tip of the medial coronoid process and the medial humeral condyle subchondral bone defect is larger. The secondary osteoarthritic changes are severe in the right and mild in the left elbow. Bilateral elbow arthroscopy is recommended.

57879

DATE

4-18-23



PATIENT

Yeti Lachanse

SPECIES

Canine

BREED

Labrador Retriever

SEX

M

AGE

1 Year

INTERPRETED BY

Nele Eley, DVM
Dr. med. Vet. DipECVDI

HOSPITAL NAME

Animal Health
Partners

REFERRING VET

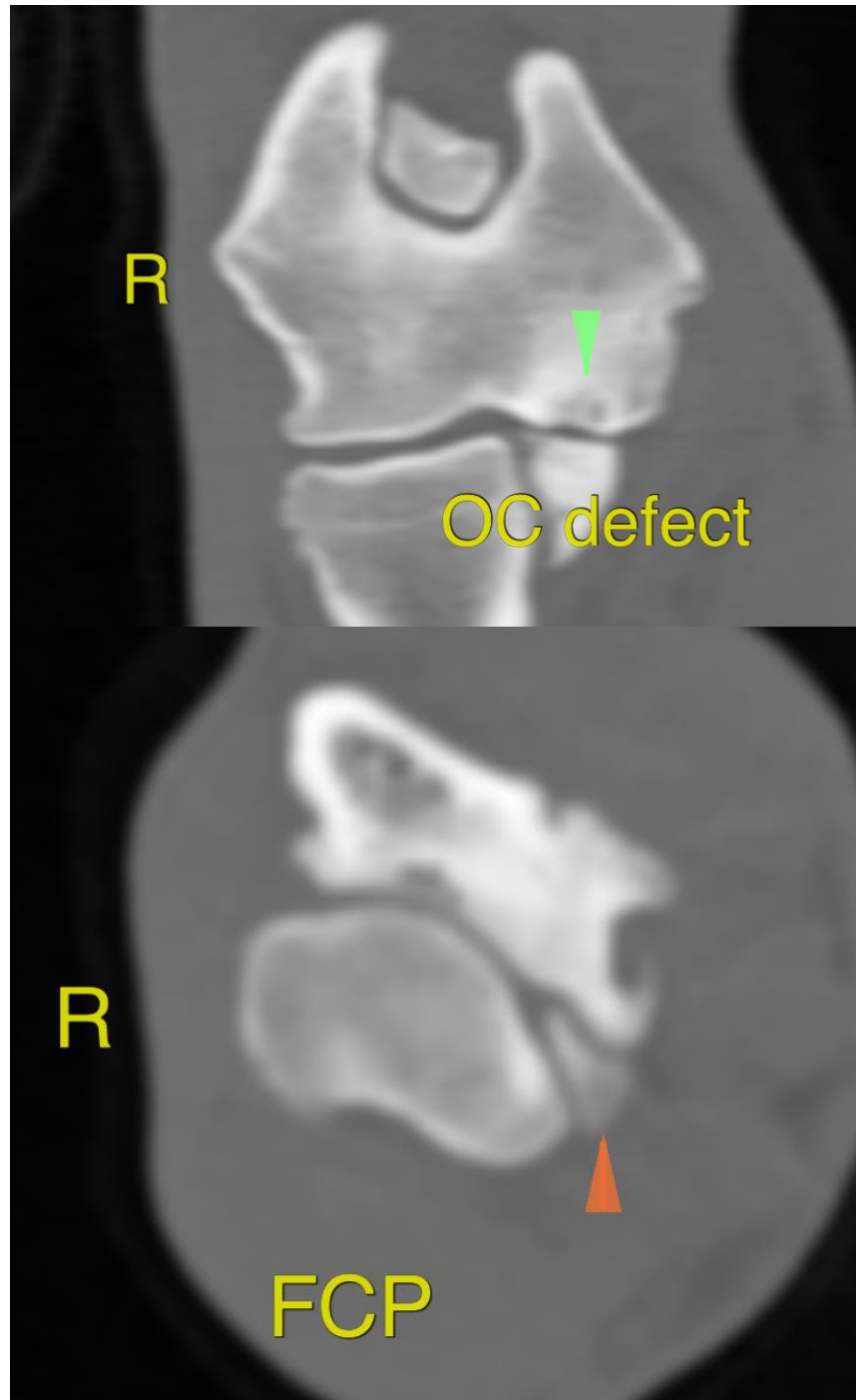Dr. Kim Murphy

INVOICE

57879

DATE

4-18-23





PATIENT

Yeti Lachanse

SPECIES

Canine

BREED

Labrador Retriever

SEX

M

AGE

1 Year

INTERPRETED BY

Nele Eley, DVM
Dr. med. Vet. DipECVDI

HOSPITAL NAME

Animal Health
Partners

REFERRING VET

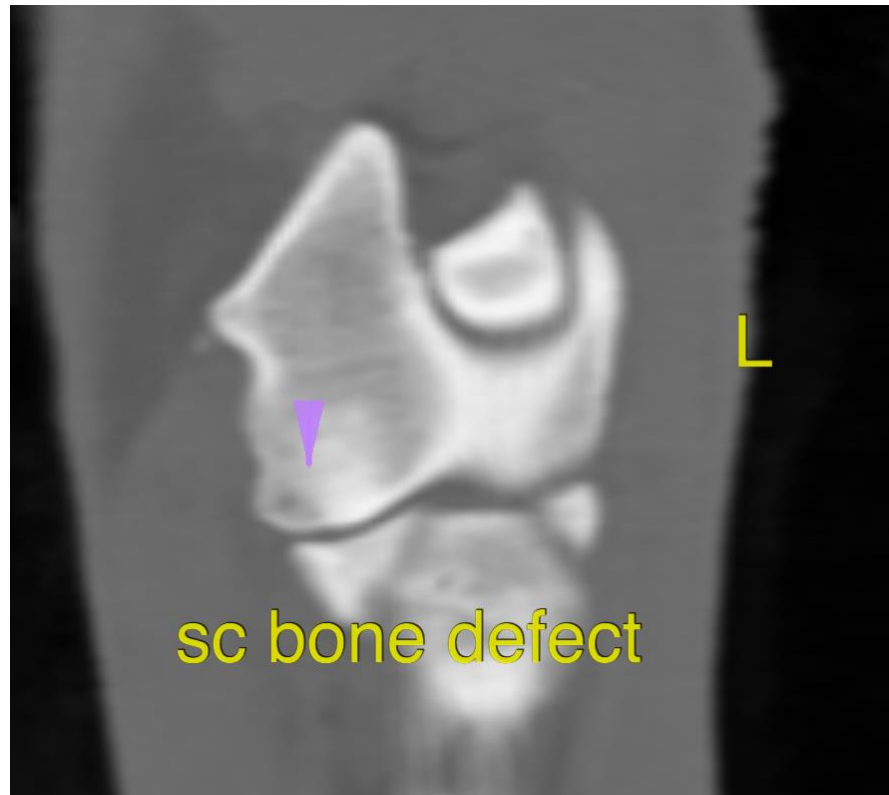
Dr. Kim Murphy

INVOICE

57879

DATE

4-18-23



The information and recommendations provided are based on the images presented by the referring veterinarian/sonographer. No evaluation can be communicated regarding pathology that was not visible in the image/video clips provided.

Thank you for this referral. If the clinical or image interpretation does not parallel your findings or if I can be of any further assistance please contact me.

Nele Eley, DVM, Dr. med. vet., DipECVDI
European Specialist in Veterinary Diagnostic Imaging, Cert. Radiology,
Senior lecturer University of Giessen, Germany, Veterinary Faculty, Department of Radiology
Nele.Eley@sonopath.com