



PATIENT

T Bakken Paws

PRESENTING CLINICAL SIGNS

CHRONIC OTITIS EXTERNA BILAT
Abnormal PE/Chem/CBC/UA Results: NEUTROPHILIA; FIV +

SPECIES

Feline

COMPUTED TOMOGRAPHIC STUDY OF THE HEAD

Plain study available for review.

BREED

DSH

COMPUTED TOMOGRAPHIC FINDINGS

Both tympanic bullae are filled with hypoattenuating material. The osseous lining of the tympanic bullae presents moderate thickening. A moderate amount of hypoattenuating material can be seen within the horizontal medial aspect of both external auditory meatuses as well.

SEX

Female

A semicircular nasopharyngeal soft tissue mass with broad base to the roof of the nasopharynx is seen to the right of the midline.

A mild amount of fluid attenuating material is present within both nasal cavities.

AGE

6 Months

COMPUTED TOMOGRAPHIC DIAGNOSIS

- Bilateral chronic otitis media and externa with nasopharyngeal polyp formation.
- Mild bilateral rhinitis - nondestructive.

INTERPRETED BY

Nele Eley, DVM
Dr. med. Vet. DipECVDI

INTERPRETATION OF THE FINDINGS & FURTHER RECOMMENDATIONS

The CT findings are compatible with chronic otitis media and externa with nasopharyngeal polyp formation. The polyp appears to connect to the right auditory tube. Consider further otoscopic workup and polyp removal.

HOSPITAL NAME

State Avenue Vet
Clinic

The concurrent presence of nondestructive rhinitis such as infectious, including viral and bacterial and less likely allergic, should be considered a possibility.

REFERRING VET

Dr. Raul Casas-Dolz

INVOICE

51618

DATE

4-18-22



PATIENT

T Bakken Paws

SPECIES

Feline

BREED

DSH

SEX

Female

AGE

6 Months

INTERPRETED BY

Nele Eley, DVM
Dr. med. Vet. DipECVDI

HOSPITAL NAME

State Avenue Vet
Clinic

REFERRING VET

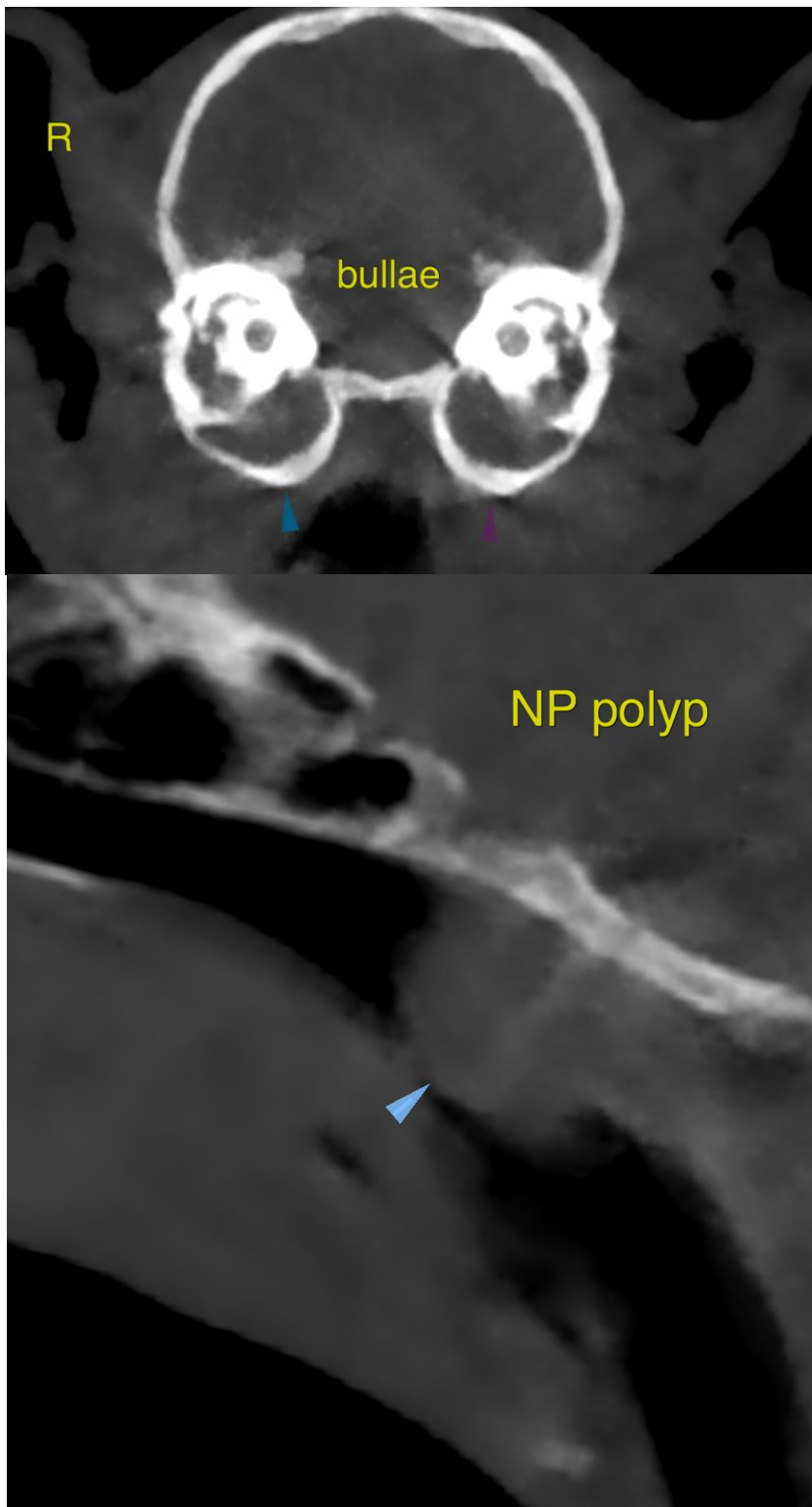
Dr. Raul Casas-Dolz

INVOICE

51618

DATE

4-18-22





PATIENT

T Bakken Paws

The information and recommendations provided are based on the images presented by the referring veterinarian/sonographer. No evaluation can be communicated regarding pathology that was not visible in the image/video clips provided.

SPECIES

Feline

Thank you for this referral. If the clinical or image interpretation does not parallel your findings or if I can be of any further assistance please contact me.

BREED

DSH

Nele Eley, DVM, Dr. med. vet., DipECVDI
European Specialist in Veterinary Diagnostic Imaging, Cert. Radiology,
Senior lecturer University of Giessen, Germany, Veterinary Faculty, Department of Radiology
Nele.Eley@sonopath.com

SEX

Female

AGE

6 Months

INTERPRETED BY

Nele Eley, DVM
Dr. med. Vet. DipECVDI

HOSPITAL NAME

State Avenue Vet
Clinic

REFERRING VET

Dr. Raul Casas-Dolz

INVOICE

51618

DATE

4-18-22