



PATIENT

Laoghaire Slezak

PRESENTING CLINICAL SIGNS

bilaterally swollen hocks. R/O autoimmune vs infectious vs arthritis. not on any meds.
Abnormal PE/Chem/CBC/UA Results: cbc/chem wnl, 4dx neg

SPECIES

Canine

ULTRASONOGRAPHIC FINDINGS

Bilateral Hocks & Achilles Regions

The ultrasonographic study reveals moderate swelling of the synovium of the tarsocrural joints. Mild anechoic fluid accumulation is seen within the visible recesses of the tarsocrural joints in both hind limbs.

BREED

Golden Retriever

The visible periarticular margins present mild osseous remodeling.

SEX

F Intact

The collateral ligaments present within normal limits.

All visible components of the achilles tendons including the superficial digital flexor tendons and gastrocnemius tendons as well as the bone surface of the calcaneal tubercle present within normal limits. There is no evidence of calcaneal bursitis.

AGE

2 Years

ULTRASONOGRAPHIC DIAGNOSIS

- Mild bilateral tarsocrural joint arthritis with mild effusion and synovialitis.
- Ultrasonographically normal achilles tendons and collateral ligaments.

INTERPRETED BY

Nele Eley, DVM
Dr. med. Vet. DipECVDI

INTERPRETATION OF THE FINDINGS & FURTHER RECOMMENDATIONS

The ultrasonographic study reveals mild tarsocrural joint effusion with synovial swelling and periarticular bone remodeling compatible with arthritis. The underlying cause of the effusion may be degenerative, inflammatory, infectious, and traumatic. Owing to the bilaterally symmetric occurrence, immune mediated arthropathy is one differential diagnosis with higher potential. Further definition, however, requires aspiration and analysis of synovia.

HOSPITAL NAME

Rockaway Animal
Hospital

The ultrasonographic presentation of the achilles tendons was within normal limits in both hind limbs.

REFERRING VET

Dr. Kahn

INVOICE

51585

DATE

4-18-22



PATIENT

Laoghaire Slezak

SPECIES

Canine

BREED

Golden Retriever

SEX

F Intact

AGE

2 Years

INTERPRETED BY

Nele Eley, DVM
Dr. med. Vet. DipECVDI

HOSPITAL NAME

Rockaway Animal
Hospital

REFERRING VET

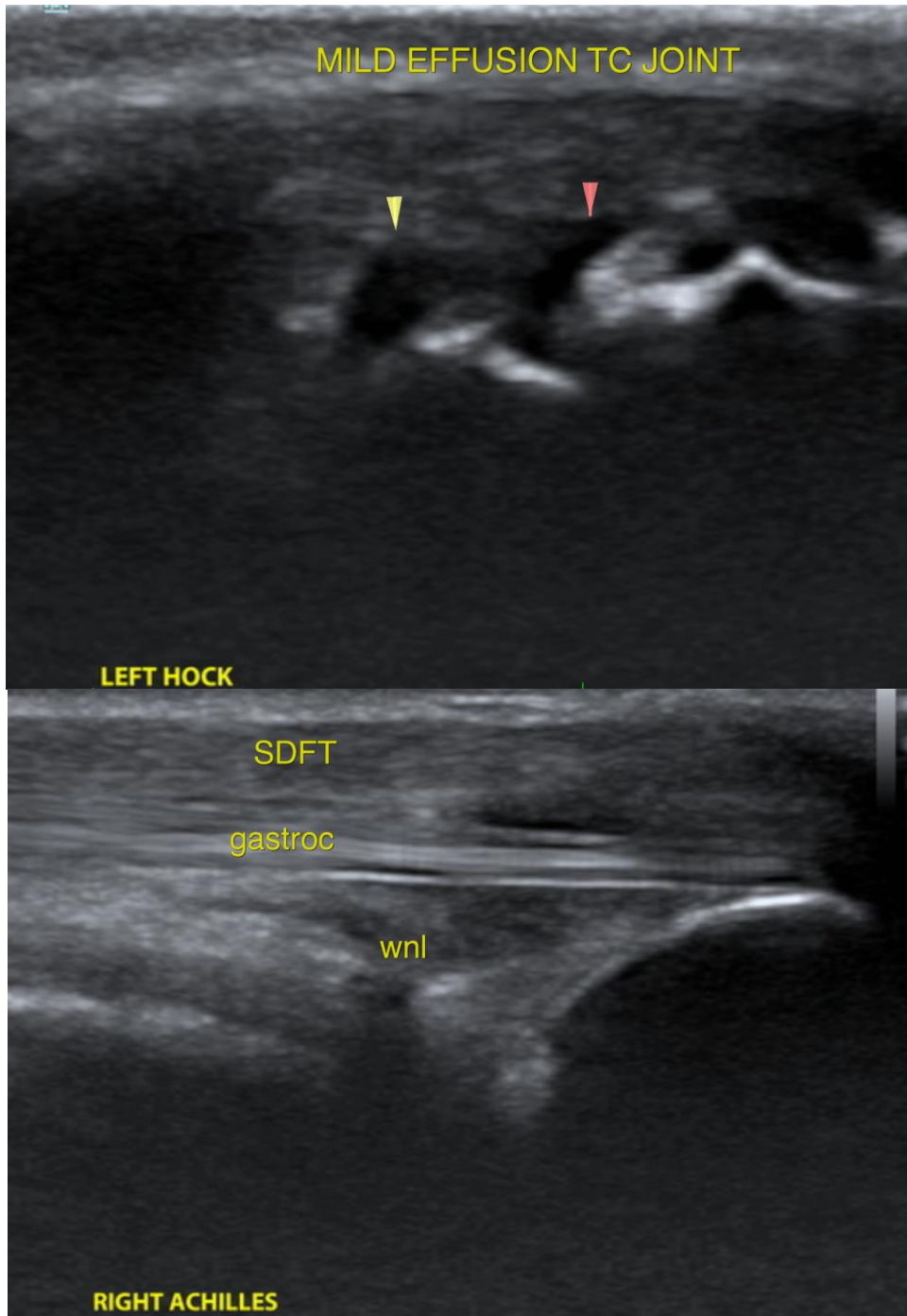
Dr. Kahn

INVOICE

51585

DATE

4-18-22





PATIENT

Laoghaire Slezak

The information and recommendations provided are based on the images presented by the referring veterinarian/sonographer. No evaluation can be communicated regarding pathology that was not visible in the image/video clips provided.

Thank you for this referral. If the clinical or image interpretation does not parallel your findings or if I can be of any further assistance please contact me.

SPECIES

Canine

Nele Eley, DVM, Dr. med. vet., DipECVDI
European Specialist in Veterinary Diagnostic Imaging, Cert. Radiology,
Senior lecturer University of Giessen, Germany, Veterinary Faculty, Department of Radiology
Nele.Eley@sonopath.com

BREED

Golden Retriever

SEX

F Intact

AGE

2 Years

INTERPRETED BY

Nele Eley, DVM
Dr. med. Vet. DipECVDI

HOSPITAL NAME

Rockaway Animal
Hospital

REFERRING VET

Dr. Kahn

INVOICE

51585

DATE

4-18-22