

**PATIENT PRESENTING CLINICAL SIGNS**

Max Garcia Max is a 9yo MN Yorkshire Terrier who presented 4/7/23 for suspected neck pain. On physical exam, swelling was noted on dorsal aspect of cranial cervical neck. At this appointment, Max was diagnosed with a fracture on right wing of C1. Max was sent home with supportive pain management, and has since improved, per owner. Current medications - Prednisone 2.5mg 1 tab PO BIDx3d, then SIDx3d, then EOD for 3 doses. Gabapentin 50mg/ml 0.7ml PO BIDx14d

SPECIES

Canine

COMPUTED TOMOGRAPHIC STUDY OF THE CERVICAL, THORACIC, & LUMBAR SPINE**BREED**

Plain and post-contrast studies available for review.

Yorkshire Terrier

COMPUTED TOMOGRAPHIC FINDINGS

The osseous anatomy of the cervical, thoracic, and lumbar spine presents within normal limits.

SEX

MN

There is no evidence of a C1 or other craniocervical junction injury. No evidence of craniocervical instability is noted.

AGE

9 Years

Number, alignment, and general anatomy of the cervical, thoracic, and lumbar vertebrae present within normal limits. No evidence of compressive or other myelopathy is seen.

The soft tissues in the neck present within normal limits.

The cervical and retropharyngeal lymph nodes present within normal limits.

INTERPRETED BYNele Eley (Ondreka),
DVM Dr. med. vet.,
DipECVDI

Both lobes of the thyroid gland present within normal limits.

COMPUTED TOMOGRAPHIC DIAGNOSIS

- Normal anatomic relationships of the cervical, thoracic, and lumbar spine.

HOSPITAL NAME

Mobile Pet Imaging

INTERPRETATION OF FINDINGS & FURTHER RECOMMENDATIONS

The CT study does not reveal evidence of structural injury, structural spinal injury, or pathology in the soft tissues of the neck. Nonstructural pathology such as inflammatory/infectious, neurodegenerative, as well as vascular cannot be ruled out and complementary csf analysis could be considered. Further definition by means of an MRI or CT myelogram could be considered in case of persisting or deteriorating clinical signs.

REFERRING VET

Seraydar

INVOICE

57822

DATE

4-17-23



PATIENT

Max Garcia

SPECIES

Canine

BREED

Yorkshire Terrier

SEX

MN

AGE

9 Years

INTERPRETED BY

Nele Eley (Ondreka),
DVM Dr. med. vet.,
DipECVDI

HOSPITAL NAME

Mobile Pet Imaging

REFERRING VET

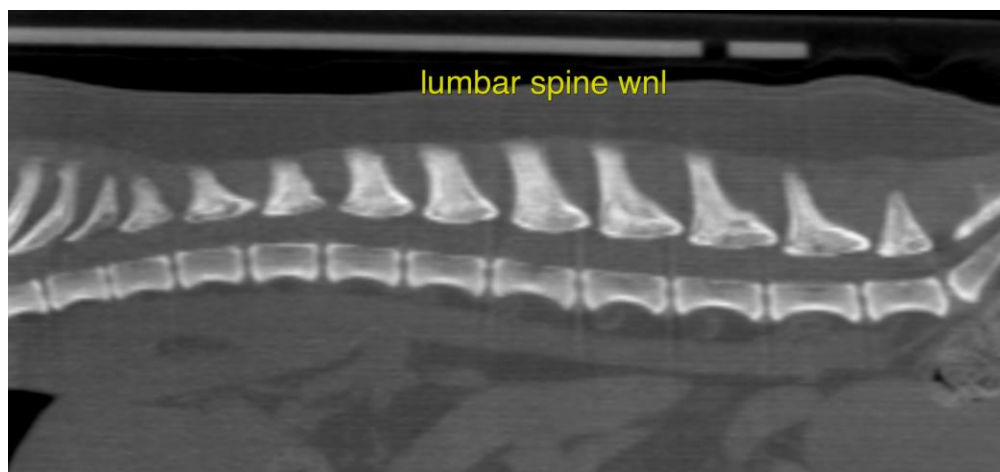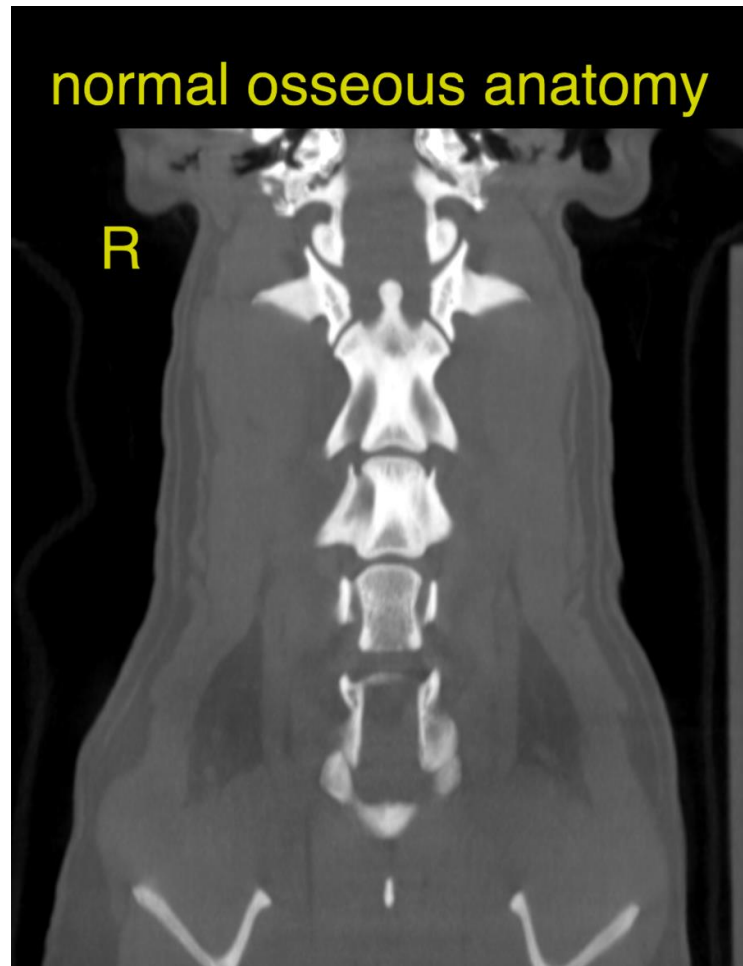
Seraydar

INVOICE

57822

DATE

4-17-23





PATIENT The information and recommendations provided are based on the images presented by the referring veterinarian. No evaluation can be communicated regarding pathology that was not visible in the image/video clips provided.

Max Garcia

SPECIES

Thank you for this referral. If the clinical or image interpretation does not parallel your findings or if I can be of any further assistance please contact me.

Canine

BREED

Nele Eley (Ondreka), DVM, Dr. med. vet., DipECVDI
European Specialist in Veterinary Diagnostic Imaging, Cert. Radiology,
Senior lecturer University of Giessen/Germany, Veterinary Faculty, Department of Radiology.
Nele.Eley@sonopath.com

Yorkshire Terrier

SEX

MN

AGE

9 Years

INTERPRETED BY

Nele Eley (Ondreka),
DVM Dr. med. vet.,
DipECVDI

HOSPITAL NAME

Mobile Pet Imaging

REFERRING VET

Seraydar

INVOICE

57822

DATE

4-17-23