

**PATIENT PRESENTING CLINICAL SIGNS**

Broco Santiago Dog bite on skull, suspected fracture noted on x-rays.
Abnormal PE/Chem/CBC/UA Results: Wound around the skull, Swollen Right submandibular area

SPECIES COMPUTED TOMOGRAPHIC STUDY OF THE HEAD

Canine Plain and post-contrast studies available for review.

COMPUTED TOMOGRAPHIC FINDINGS

BREED
Schnauzer
The CT study shows a fracture of the right mandible's coronoid process. The tip of the right mandible's coronoid process is fractured in two pieces. One semicircular 16 x 8mm sized, and a thinner 12 x 3mm sized fragment. Both fragments are displaced caudally. The temporomandibular joint is not involved and in situ. The rest of the right mandible and the left mandible as well as the left temporomandibular joint are intact. There is no evidence of maxillary or calvarial bone fracture.

SEX

Male Extensive soft tissue swelling is noted in the submandibular area to the right of the midline represented by subcutaneous and interfascial fat stranding which can be traced into the right retropharyngeal area.

AGE

Mild right retropharyngeal lymphadenomegaly is noted.

5 Years

COMPUTED TOMOGRAPHIC DIAGNOSIS

- Complete acute traumatic fractures of the right mandible's coronoid process with caudal displacement – No evidence of temporomandibular joint involvement.
- Extensive soft tissue swelling in the right temporomandibular joint and submandibular area compatible with regional hemorrhage.
- Right medial retropharyngeal lymphadenomegaly compatible with reactive hyperplasia.

INTERPRETED BY

Nele Eley (Ondreka),
DVM Dr. med. vet.,
DipECVDI

INTERPRETATION OF FINDINGS & FURTHER RECOMMENDATIONS**HOSPITAL NAME**

Mobile Pet Imaging
CFL

The CT study reveals fracturing of the right mandible's coronoid process with two fracture fragments originating from the tip of the coronoid process and being displaced caudally. There is no evidence of temporomandibular joint involvement and no evidence of involvement of the neurocranium.

REFERRING VET

Meaux

INVOICE

57839

DATE

4-17-23



PATIENT

Broco Santiago

SPECIES

Canine

BREED

Schnauzer

SEX

Male

AGE

5 Years

INTERPRETED BY

Nele Eley (Ondreka),
DVM Dr. med. vet.,
DipECVDI

HOSPITAL NAME

Mobile Pet Imaging
CFL

REFERRING VET

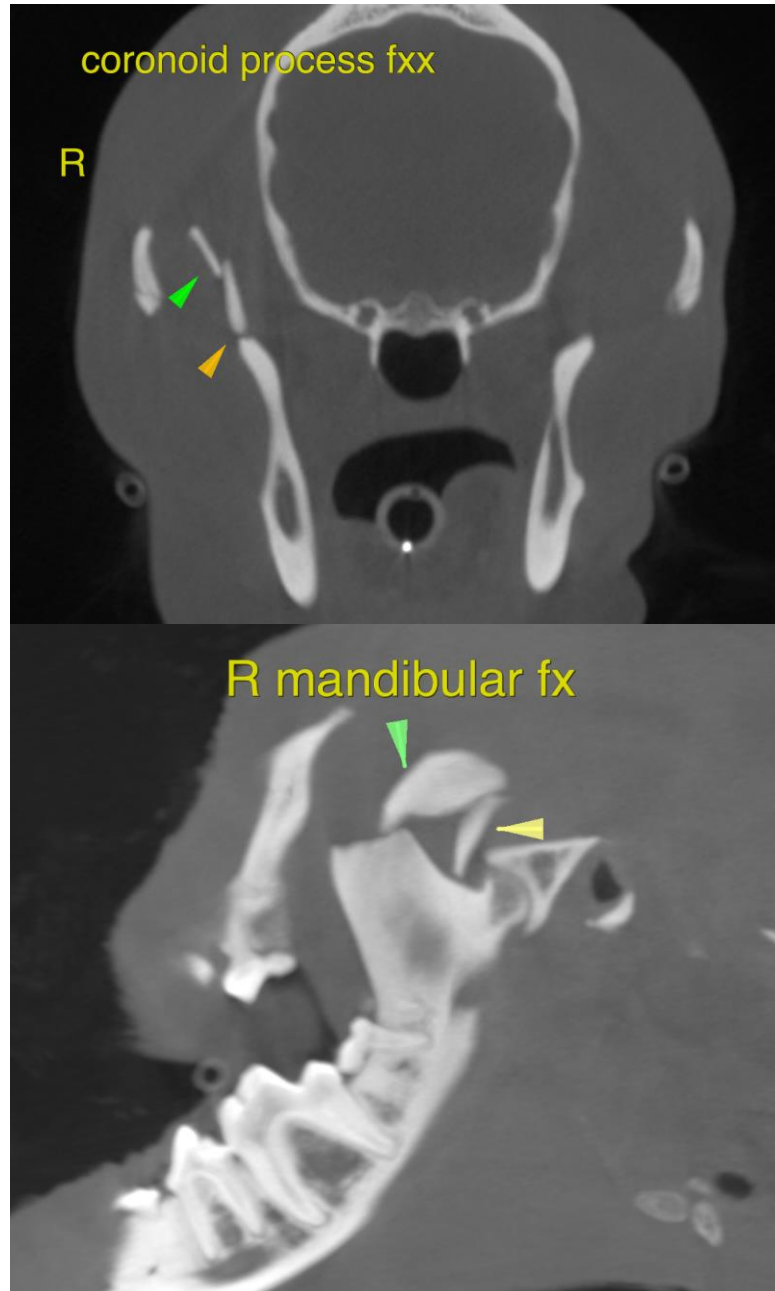
Meaux

INVOICE

57839

DATE

4-17-23



**PATIENT**

Broco Santiago

The information and recommendations provided are based on the images presented by the referring veterinarian. No evaluation can be communicated regarding pathology that was not visible in the image/video clips provided.

SPECIES

Canine

Thank you for this referral. If the clinical or image interpretation does not parallel your findings or if I can be of any further assistance please contact me.

BREED

Schnauzer

Nele Eley (Ondreka), DVM, Dr. med. vet., DipECVDI
European Specialist in Veterinary Diagnostic Imaging, Cert. Radiology,
Senior lecturer University of Giessen/Germany, Veterinary Faculty, Department of Radiology.
Nele.Eley@sonopath.com

SEX

Male

AGE

5 Years

INTERPRETED BY

Nele Eley (Ondreka),
DVM Dr. med. vet.,
DipECVDI

HOSPITAL NAME

Mobile Pet Imaging
CFL

REFERRING VET

Meaux

INVOICE

57839

DATE

4-17-23