



**PATIENT**

Long Long Gu

**SPECIES**

Canine

**BREED**

Siberian Husky

**SEX**

MN

**AGE**

7 Years

**INTERPRETED BY**

Nele Eley, DVM  
Dr. med. Vet. DipECVDI

**HOSPITAL NAME**

Animal Health  
Partners

**REFERRING VET**

Dr. Alison Little

**INVOICE**

57810

**DATE**

4-14-23

**PRESENTING CLINICAL SIGNS**

Back pain. reluctant to jump. Whining a lot at home. Uncomfortable sitting. Was seen April 2nd and prescribed metacam and gabapentin. Has been static since. Mentation: Bright, alert and responsive. Cranial nerve exam: No deficits noted. Gait/posture: Ambulatory with no ataxia or paresis. Postural reactions: Proprioceptive positioning and hopping were normal in all limbs. Spinal reflexes: Normal. Sensory/nociception: Hyperesthesia on palpation of the cranial lumbar spine. Localization - T3-L3 myelopathy

**MAGNETIC RESONANCE IMAGING STUDY OF THE THORACIC & LUMBAR SPINE**

T2, T1-non and fat-saturated, plain and post-contrast sequences in various image planes available for review.

**MAGNETIC RESONANCE IMAGING FINDINGS**

Mild to moderate protrusion of the T12/13 intervertebral annulus fibrosus into the ventral epidural space is seen. There is mild flattening of the spinal cord. No deviation or compression of the spinal cord is noted. There is no signal alteration of the spinal cord, and the lateral and dorsal epidural space is maintained.

Moderate T13/L1 annulus fibrosus protrusion into the ventral epidural space is seen. There is moderate flattening of the spinal cord without obvious deviation, compression, or signal alteration. The lateral and dorsal epidural spaces are maintained.

Mild to moderate lumbosacral intervertebral disc protrusion and mild hypertrophy of the ligamentum flavum are seen at the lumbosacral junction.

Mild L6/7 intervertebral disc protrusion is noted as well.

A 5mm sized nodule is seen within the cranial pole of the left adrenal gland.

**MAGNETIC RESONANCE IMAGING DIAGNOSIS**

- Moderate chronic intervertebral disc protrusion T13/L1.
- Mild to moderate chronic intervertebral disc protrusion T12/13.
- Mild to moderate degenerative lumbosacral stenosis.
- Mild chronic protrusion L6/7.
- Small left adrenal gland nodule.

**INTERPRETATION OF THE FINDINGS & FURTHER RECOMMENDATIONS**

The MRI study reveals moderate chronic intervertebral disc protrusion at the thoracolumbar junction between T13 and L1. Mild ventral flattening of the spinal cord is seen. The MRI findings appear to correlate with the clinical signs of the patient. The T12/13 intervertebral disc protrusion is milder but may contribute to the clinical signs as well.

The findings of the caudal lumbar spine and lumbosacral junction require clinical correlation. Mild to moderate degenerative lumbosacral stenosis is present. The clinical significance of these changes, however, can vary.



**PATIENT**

Long Long Gu

Differential diagnosis for the left adrenal gland nodule includes early adenoma, adenocarcinoma, pheochromocytoma, and incidentaloma / myelolipoma.

**SPECIES**

Canine

**BREED**

Siberian Husky

**SEX**

MN

**AGE**

7 Years

**INTERPRETED BY**

Nele Eley, DVM  
Dr. med. Vet. DipECVDI

**HOSPITAL NAME**

Animal Health  
Partners

**REFERRING VET**

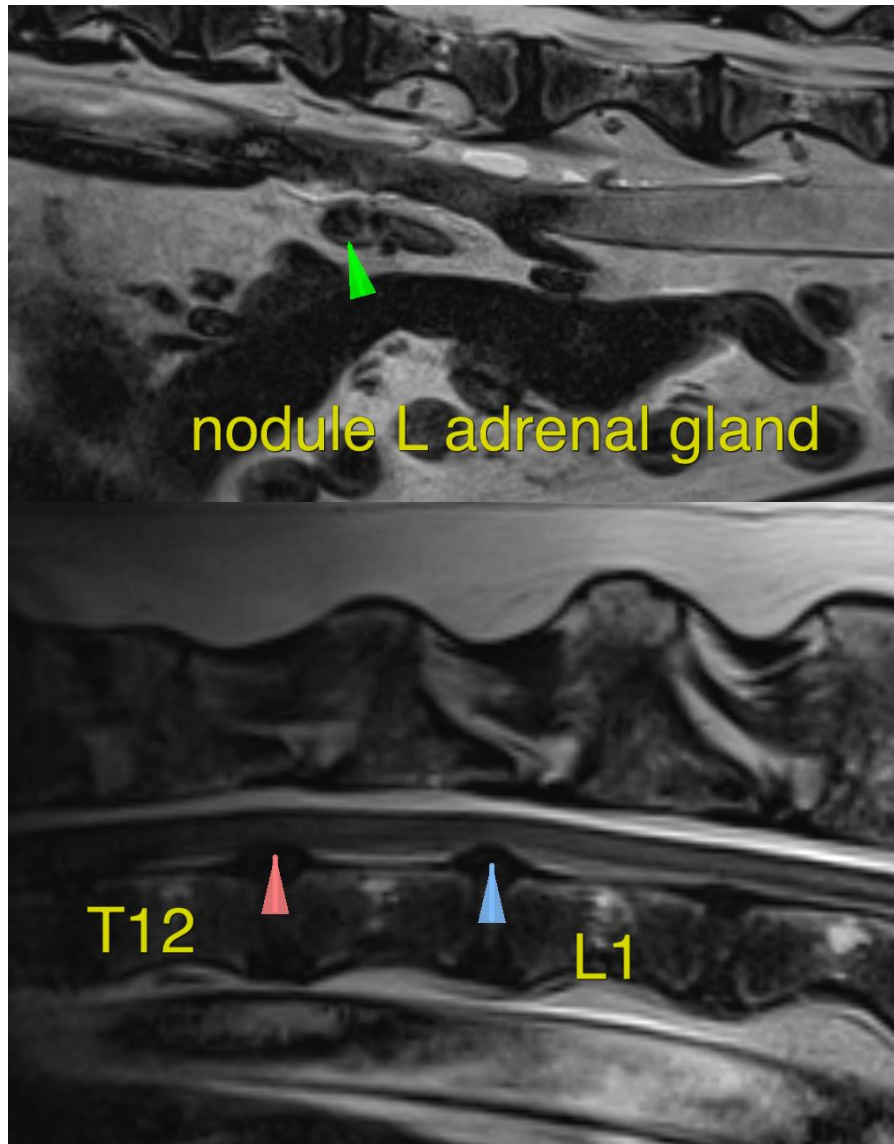
Dr. Alison Little

**INVOICE**

57810

**DATE**

4-14-23





**PATIENT**

Long Long Gu

**SPECIES**

Canine

**BREED**

Siberian Husky

**SEX**

MN

**AGE**

7 Years

**INTERPRETED BY**

Nele Eley, DVM  
Dr. med. Vet. DipECVDI

**HOSPITAL NAME**

Animal Health  
Partners

**REFERRING VET**

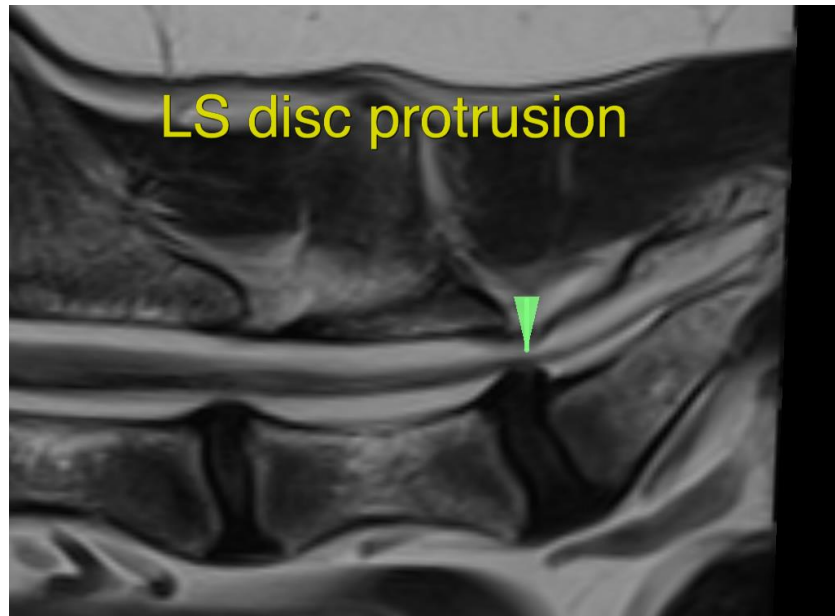
Dr. Alison Little

**INVOICE**

57810

**DATE**

4-14-23



The information and recommendations provided are based on the images presented by the referring veterinarian/sonographer. No evaluation can be communicated regarding pathology that was not visible in the image/video clips provided.

Thank you for this referral. If the clinical or image interpretation does not parallel your findings or if I can be of any further assistance please contact me.

**Nele Eley**, DVM, Dr. med. vet., DipECVDI  
European Specialist in Veterinary Diagnostic Imaging, Cert. Radiology,  
Senior lecturer University of Giessen, Germany, Veterinary Faculty, Department of Radiology  
Nele.Eley@sonopath.com