

**PATIENT**

Puck McClain

PRESENTING CLINICAL SIGNS

Pet is painful on palpation around TL junction--no neurological deficits but owner reports is slowly improving, suspect IVDD

SPECIES

Canine

COMPUTED TOMOGRAPHIC STUDY OF THE LUMBOSACRAL SPINE

Plain and post IV contrast studies available for review.

BREED

Goldendoodle

COMPUTED TOMOGRAPHIC FINDINGS

Moderate lumbosacral intervertebral disc protrusion into the ventral epidural space of the vertebral canal is seen. Mild smooth new bone formation of the lumbosacral vertebral endplates is noted too. There is no evidence for neuroforaminal stenosis.

SEX

MN

Moderate L6/7 intervertebral disc herniation over the intervertebral disc space is seen. There also is a partially mineralized, cranially migrated herniation in the right ventral epidural space over the caudal half of L6. Mild right neuroforaminal extension is noted.

Mild protrusion of the L5/6 intervertebral disc is noted as well.

AGE

11

COMPUTED TOMOGRAPHIC DIAGNOSIS

- Moderate degenerative lumbosacral stenosis
- Mild lumbosacral spondylosis deformans
- Moderate presumably chronic extrusion L6/7
- Mild chronic L5/6 intervertebral disc protrusion

INTERPRETED BY

Nele Eley, DVM
Dr. med. Vet. DipECVDI

INTERPRETATION OF THE FINDINGS & FURTHER RECOMMENDATIONS**HOSPITAL NAME**

Advanced Animal
Imaging

The CT study reveals moderate chronic degenerative lumbosacral stenosis. There also is a moderate partially mineralized disc herniation at L6/7 which appears to represent an organized / chronic extrusion with cranial migration over L6 and may add to the compression of the cauda equina potentially.

The protrusion over L5/6 appears to be milder and its clinical significance is uncertain.

REFERRING VET

Blair Hollowell

INVOICE

57788

DATE

4-13-23



PATIENT

Puck McClain

SPECIES

Canine

BREED

Goldendoodle

SEX

MN

AGE

11

INTERPRETED BY

Nele Eley, DVM
Dr. med. Vet. DipECVDI

HOSPITAL NAME

Advanced Animal
Imaging

REFERRING VET

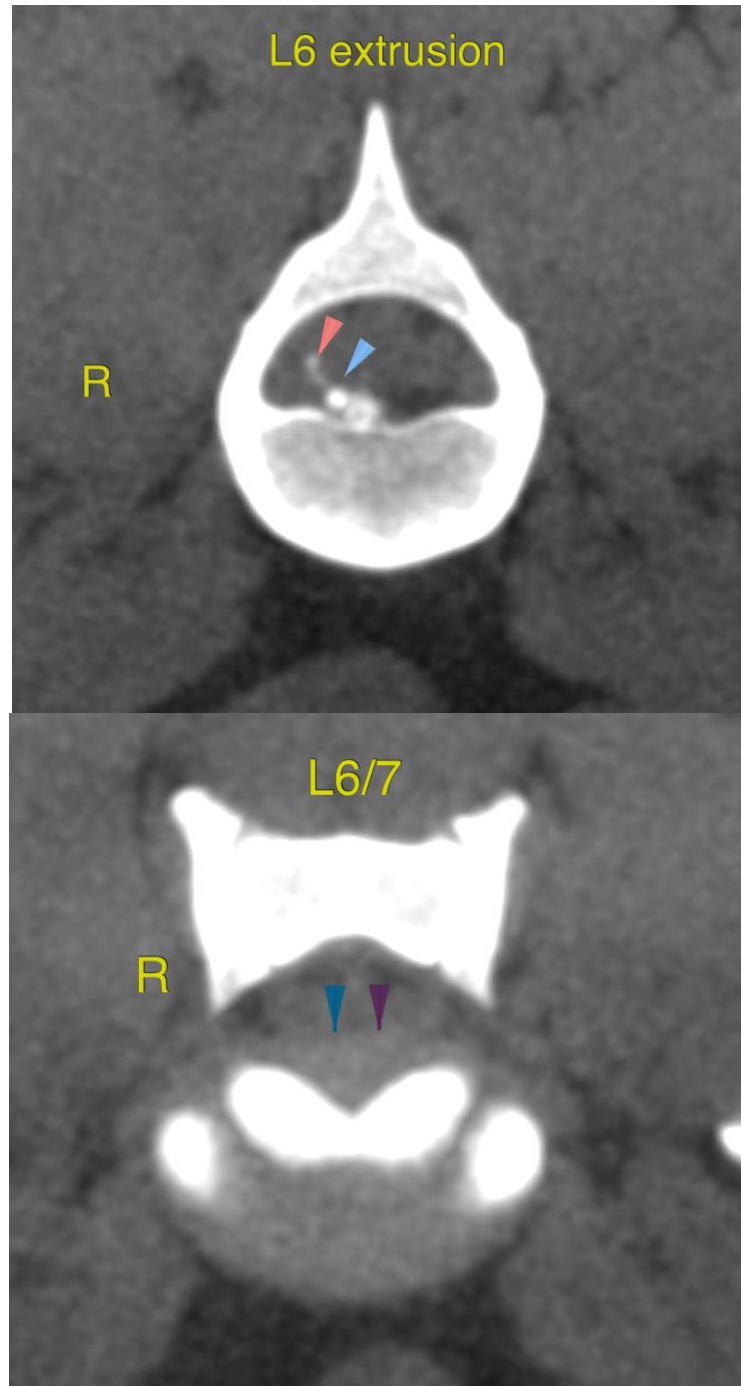
Blair Hollowell

INVOICE

57788

DATE

4-13-23





PATIENT

Puck McClain

SPECIES

Canine

BREED

Goldendoodle

SEX

MN

AGE

11

INTERPRETED BY

Nele Eley, DVM
Dr. med. Vet. DipECVDI

HOSPITAL NAME

Advanced Animal
Imaging

REFERRING VET

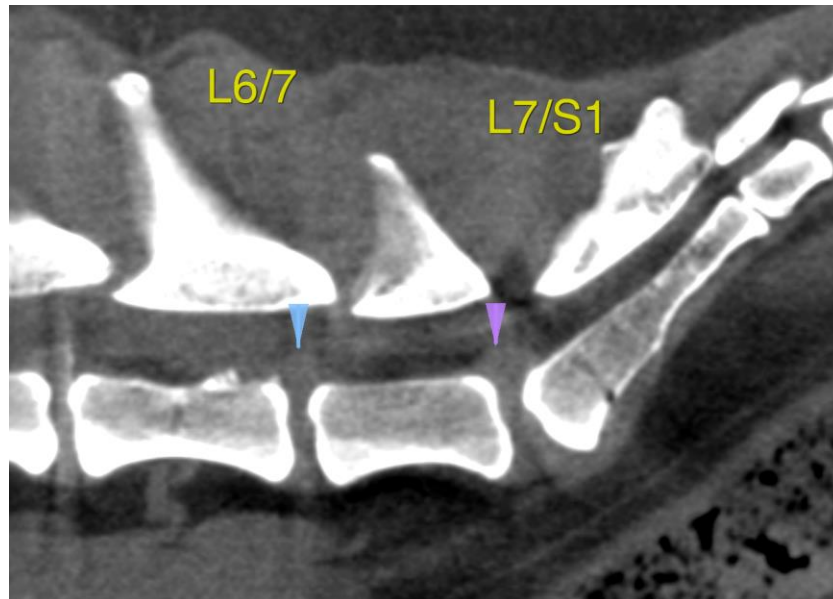
Blair Hollowell

INVOICE

57788

DATE

4-13-23



The information and recommendations provided are based on the images presented by the referring veterinarian/sonographer. No evaluation can be communicated regarding pathology that was not visible in the image/video clips provided.

Thank you for this referral. If the clinical or image interpretation does not parallel your findings or if I can be of any further assistance please contact me.

Nele Eley, DVM, Dr. med. vet., DipECVDI
European Specialist in Veterinary Diagnostic Imaging, Cert. Radiology,
Senior lecturer University of Giessen, Germany, Veterinary Faculty, Department of Radiology
Nele.Eley@sonopath.com