

**PATIENT PRESENTING CLINICAL SIGNS**

Calogero Ciciless Mild dyspnea, stertor, sneezing/ coughing. Improved on nebulizing. On rads: linear structure seen in caudal lung fields esp noted on VD view, in addition to bronchitis which has greatly improved on nebulizing. Concern for diaphragmatic hernia.

**SPECIES COMPUTED TOMOGRAPHIC STUDY OF THE THORAX**

Lagamorphy Plain and post contrast studies available for review.

**BREED COMPUTED TOMOGRAPHIC FINDINGS**

Rabbit A 4 x 4.5 cm sized expansile hypoenhancing mass is seen in the left division of the liver.

**SEX** A 1.4 x 1.6 cm sized soft tissue attenuating nodule with heterogenous enhancement is seen in the right caudal lung lobe. Multiple 2-4 mm sized interstitial pulmonary nodules in the remainder of the right and left lung are also noted.

Neutered Male The mediastinal lymph nodes present within normal limits.

**AGE COMPUTED TOMOGRAPHIC DIAGNOSIS**

- 8 Years
- Large expansile left divisional liver mass.
  - Multiple pulmonary interstitial nodules

**INTERPRETATION OF FINDINGS & FURTHER RECOMMENDATIONS****INTERPRETED BY**

Nele Eley (Ondreka),  
DVM Dr. med. vet.,  
DipECVDI

The CT study reveals a large expansile left divisional liver mass meeting neoplastic criteria. Lymphoma and hepatocellular carcinoma are primary differential diagnoses. Final diagnosis would require sampling. The mass is in a resectable position.

However, the multiple pulmonary nodules suggest high odds for metastatic disease. Granulomatous disease can never be ruled out entirely but is by far less likely.

**HOSPITAL NAME**

Mobile Pet Imaging

**REFERRING VET**

Meaux

**INVOICE**

57783

**DATE**

4-13-23



**PATIENT**

Calogero Ciciless

**SPECIES**

Lagomorphy

**BREED**

Rabbit

**SEX**

Neutered Male

**AGE**

8 Years

**INTERPRETED BY**

Nele Eley (Ondreka),  
DVM Dr. med. vet.,  
DipECVDI

**HOSPITAL NAME**

Mobile Pet Imaging

**REFERRING VET**

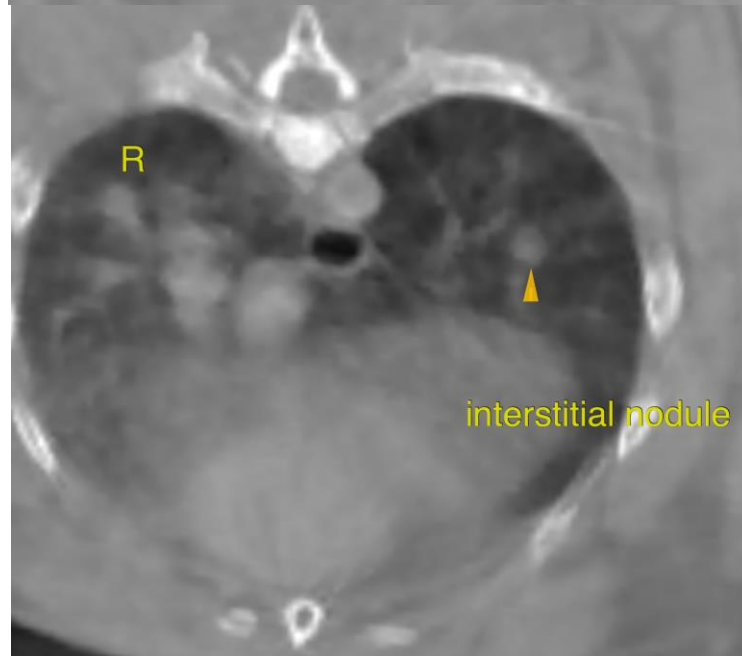
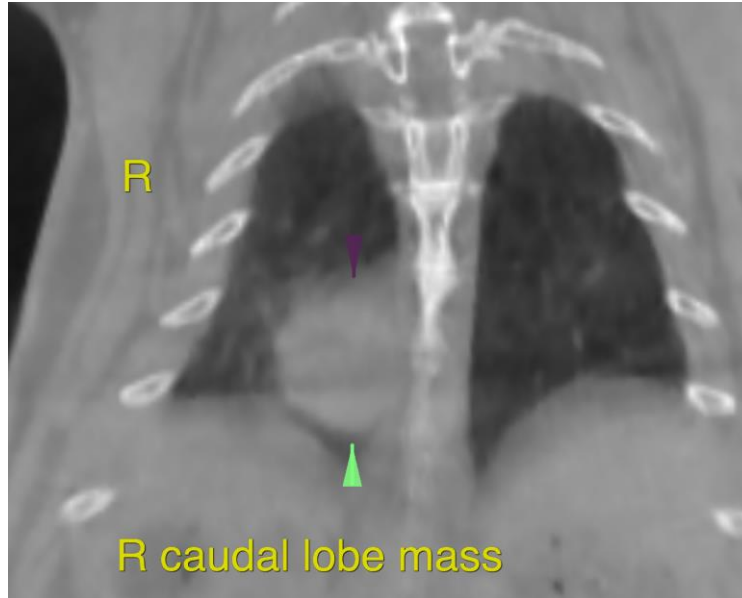
Meaux

**INVOICE**

57783

**DATE**

4-13-23





**PATIENT**

Calogero Ciciless

**SPECIES**

Lagamorphy

**BREED**

Rabbit

**SEX**

Neutered Male

**AGE**

8 Years

**INTERPRETED BY**

Nele Eley (Ondreka),  
DVM Dr. med. vet.,  
DipECVDI

**HOSPITAL NAME**

Mobile Pet Imaging

**REFERRING VET**

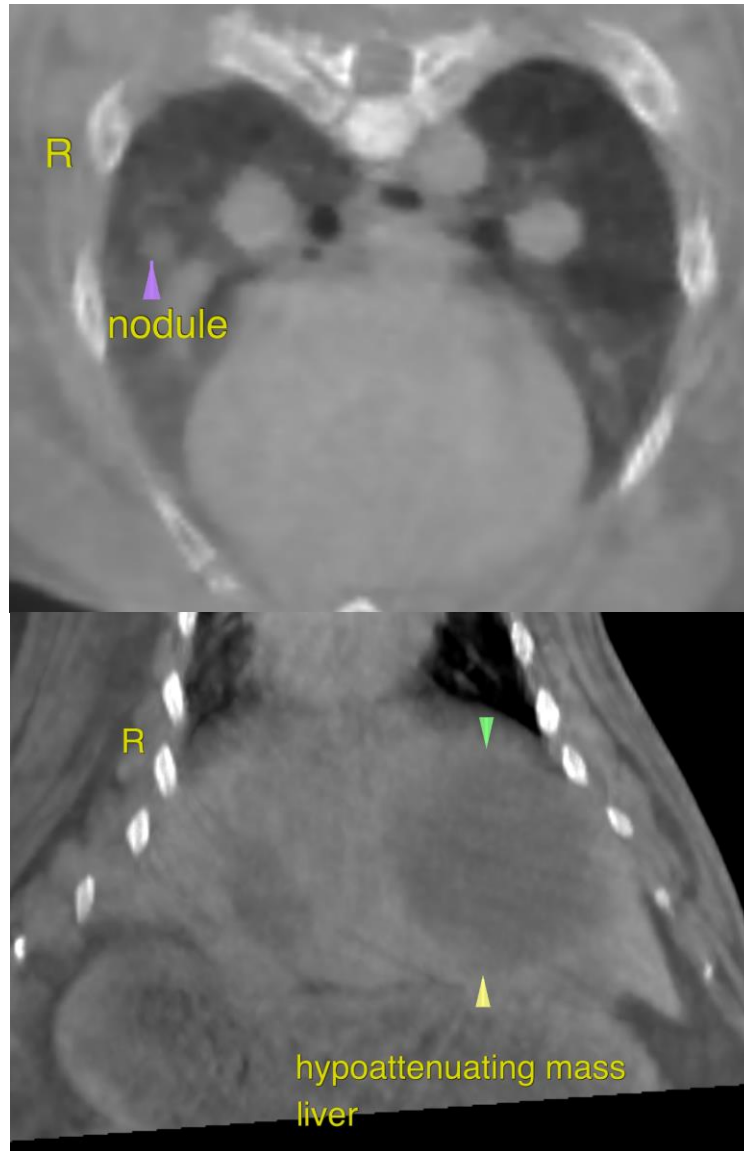
Meaux

**INVOICE**

57783

**DATE**

4-13-23



The information and recommendations provided are based on the images presented by the referring veterinarian. No evaluation can be communicated regarding pathology that was not visible in the image/video clips provided.

Thank you for this referral. If the clinical or image interpretation does not parallel your findings or if I can be of any further assistance please contact me.

**Nele Eley (Ondreka)**, DVM, Dr. med. vet., DipECVDI  
European Specialist in Veterinary Diagnostic Imaging, Cert. Radiology,  
Senior lecturer University of Giessen/Germany, Veterinary Faculty, Department of Radiology.  
Nele.Eley@sonopath.com