



PATIENT

Tracy Reyes

PRESENTING CLINICAL SIGNS

Has mammary tumors, not spayed, preanesthetic blood work was normal. U/A showed wbc, and rbc's. Was in heat two weeks ago and is now PU/PD. Pyometra?? Cystitis?? No discharge from vulva seen by owner

SPECIES

Canine

RADIOGRAPHIC STUDY OF THE THORAX & ABDOMEN

Right lateral whole body view and lateral and ventrodorsal view of the abdomen totaling 4 images available for review.

BREED

Silky

RADIOGRAPHIC FINDINGS

Thorax

The surrounding bony structures are within normal limits.

SEX

F

The extrathoracic soft tissues present homogeneous without abnormalities.

AGE

11 Years

The heart is of normal size and shape and there is no evidence of cardiac chamber or vascular enlargement. The pulmonary vasculature is within normal limits. The vertebral heart score is 10.

The cranial mediastinum presents the expected soft tissue opacity. The mediastinal width is less than twice the width of the vertebral column at the same level.

INTERPRETED BY

Nele Eley, DVM
Dr. med. Vet. DipECVDI

Mild redundancy of the dorsal tracheal ligament is seen in the caudal cervical trachea.

A moderate bronchial lung pattern with mild cylindrical bronchiectasis is noted.

The diaphragm is well delineated with even surface and the expected mild cranial bulging of the diaphragmatic cupola.

HOSPITAL NAME

Barry Magill

Abdomen

The mamils are prominent.

REFERRING VET

Dr. Magill

The abdominal cavity appears to be voluminous.

The abdominal serosal detail is maintained.

Tubular soft tissue opacities superimpose onto the urinary bladder.

INVOICE

51508

No overt uterine body/cervix enlargement can be seen.

The colon contains a moderate amount of inspissated fecal matter.

DATE

4-13-22

A mild amount of gravel is seen within the stomach.

The liver and spleen present within normal limits.

The osseous structures present within age related normal limits.



PATIENT

Tracy Reyes

RADIOGRAPHIC DIAGNOSIS

- Potential for uterine horn enlargement.
- Moderate bronchial lung pattern.

SPECIES

Canine

INTERPRETATION OF THE FINDINGS & FURTHER RECOMMENDATIONS

Enlargement of the uterine horns is entirely possible based on the radiographic findings. However, the uterine enlargement, if present, does not appear to be extensive at this point.

BREED

Silky

The urinary bladder presents within normal radiographic limits. Further definition by means of ultrasound could be considered in order to further define for presence of lower urinary tract pathology and degree as well as type of uterine enlargement.

SEX

F

The bronchial lung pattern with bronchiectasis suggests presence of chronic lower airway disease. Low grade eosinophilic bronchopneumopathy or infectious bronchitis such as viral, bacterial, or parasitic are potential considerations. However, further definition is only indicated in case of pertinent clinical signs.

AGE

11 Years

INTERPRETED BY

Nele Eley, DVM
Dr. med. Vet. DipECVDI

HOSPITAL NAME

Barry Magill

REFERRING VET

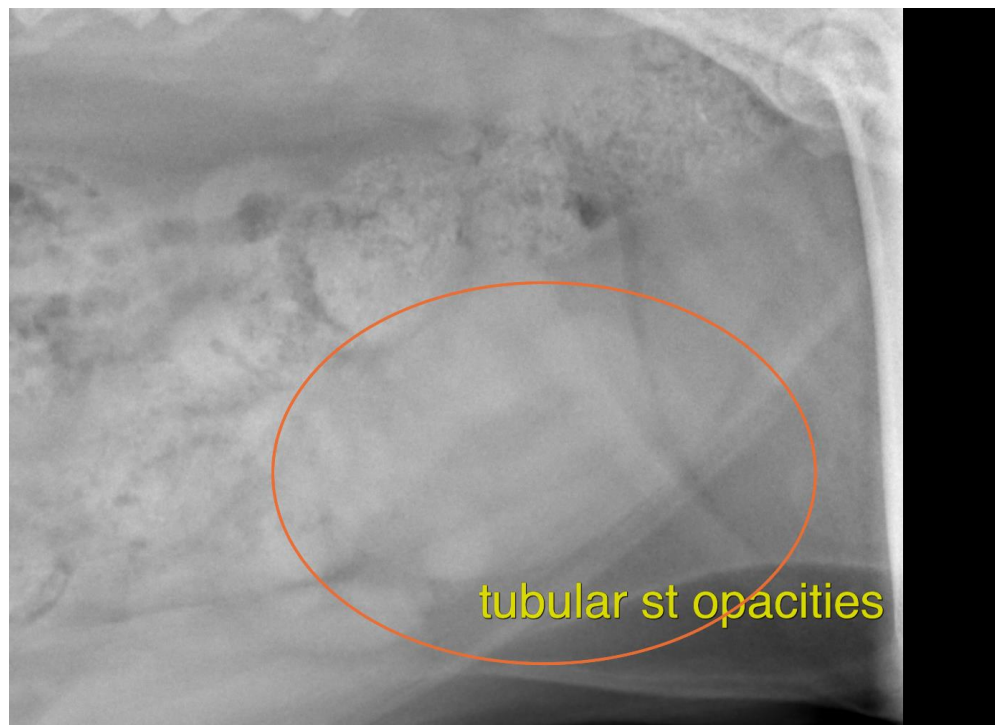
Dr. Magill

INVOICE

51508

DATE

4-13-22





PATIENT

Tracy Reyes

SPECIES

Canine

BREED

Silky

SEX

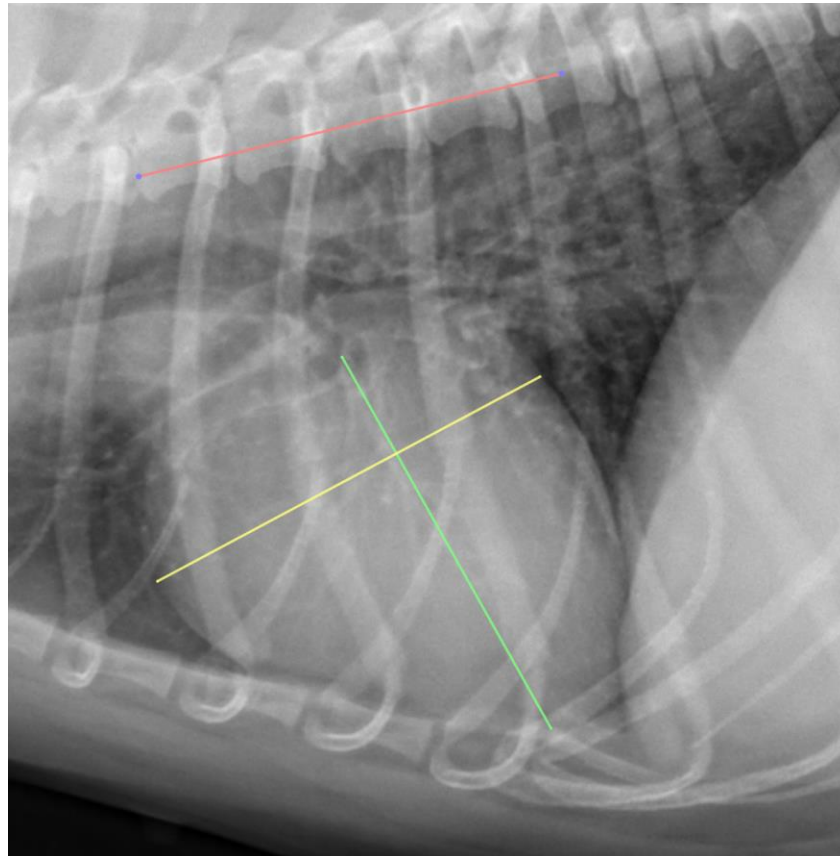
F

AGE

11 Years

INTERPRETED BY

Nele Eley, DVM
Dr. med. Vet. DipECVDI



HOSPITAL NAME

Barry Magill

The information and recommendations provided are based on the images presented by the referring veterinarian/sonographer. No evaluation can be communicated regarding pathology that was not visible in the image/video clips provided.

REFERRING VET

Dr. Magill

Thank you for this referral. If the clinical or image interpretation does not parallel your findings or if I can be of any further assistance please contact me.

Nele Eley, DVM, Dr. med. vet., DipECVDI
European Specialist in Veterinary Diagnostic Imaging, Cert. Radiology,
Senior lecturer University of Giessen, Germany, Veterinary Faculty, Department of Radiology
Nele.Eley@sonopath.com

INVOICE

51508

DATE

4-13-22