

**PATIENT**

Suki Drvol

PRESENTING CLINICAL SIGNS

Intermittent, random coughing for several years. Has increased suddenly to daily coughing episodes, exacerbated by activity. History of seizures - on Bromide On Galliprant/Gabapentin for hind leg lameness issues.

SPECIES

Canine

RADIOGRAPHIC STUDY OF THE THORAX

Right/left lateral and ventrodorsal views totaling 4 images available for review.

BREED

Poo/Shih

RADIOGRAPHIC FINDINGS

Mild bilateral elbow osteoarthritis is noted.

The extrathoracic soft tissues present homogeneous without abnormalities.

SEX

FS

The heart is of normal size and shape and there is no evidence of cardiac chamber or vascular enlargement. The pulmonary vasculature is within normal limits. The vertebral heart score is 10.

AGE

12 Years, 6 Months

The cranial mediastinum presents the expected soft tissue opacity. The mediastinal width is less than twice the width of the vertebral column at the same level.

Moderate dorsoventral flattening of the cervical trachea and mild upper esophageal aerophagia are seen.

INTERPRETED BY

Nele Eley, DVM
Dr. med. Vet. DipECVDI

The degree of pulmonary inflation is fair. A mild generalized bronchial lung pattern is seen and evenly distributed throughout the lung.

The diaphragm is well delineated with even surface and the expected mild cranial bulging of the diaphragmatic cupola.

HOSPITAL NAME

Gentle Doctor Animal
Hospital

The stomach is post-prandial.

RADIOGRAPHIC DIAGNOSIS

- Dynamic tracheal disease.
- No evidence of mediastinal widening.
- Mild bronchial lung pattern.

REFERRING VET

Dr. Miranda
Thomassen

INTERPRETATION OF THE FINDINGS & FURTHER RECOMMENDATIONS

The radiographic findings of the mediastinum are within normal limits.

INVOICE

51510

There is evidence of dynamic trachea disease accentuating the cervical trachea. Moreover, a mild bronchial lung pattern is noted and may be due to allergic/eosinophilic bronchopneumopathy or infectious bronchitis such as viral, bacterial, or parasitic. Consider further definition by means of airway endoscopy with airway sampling.

DATE

4-13-22



PATIENT

Suki Drvol

SPECIES

Canine

BREED

Poo/Shih

SEX

FS

AGE

12 Years, 6 Months

INTERPRETED BY

Nele Eley, DVM
Dr. med. Vet. DipECVDI

HOSPITAL NAME

Gentle Doctor Animal
Hospital

REFERRING VET

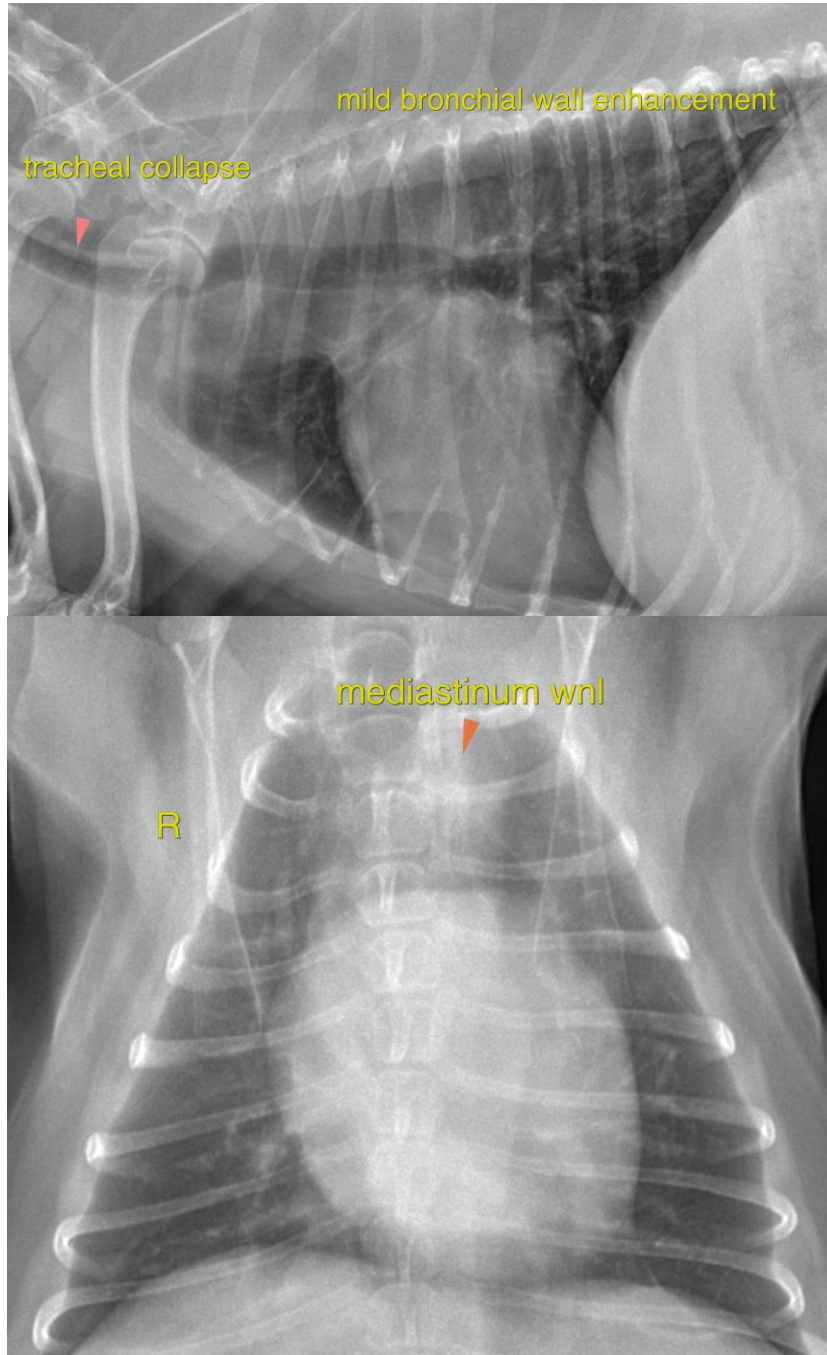
Dr. Miranda
Thomassen

INVOICE

51510

DATE

4-13-22





PATIENT

Suki Drvol

The information and recommendations provided are based on the images presented by the referring veterinarian/sonographer. No evaluation can be communicated regarding pathology that was not visible in the image/video clips provided.

Thank you for this referral. If the clinical or image interpretation does not parallel your findings or if I can be of any further assistance please contact me.

SPECIES

Canine

Nele Eley, DVM, Dr. med. vet., DipECVDI
European Specialist in Veterinary Diagnostic Imaging, Cert. Radiology,
Senior lecturer University of Giessen, Germany, Veterinary Faculty, Department of Radiology
Nele.Eley@sonopath.com

BREED

Poo/Shih

SEX

FS

AGE

12 Years, 6 Months

INTERPRETED BY

Nele Eley, DVM
Dr. med. Vet. DipECVDI

HOSPITAL NAME

Gentle Doctor Animal
Hospital

REFERRING VET

Dr. Miranda
Thomassen

INVOICE

51510

DATE

4-13-22