



PATIENT

Abbie Owen

PRESENTING CLINICAL SIGNS

Tachypnea, no obvious lung sounds. Not eating/drinking. Uncooperative for rads.

SPECIES

Feline

RADIOGRAPHIC STUDY OF THE THORAX

Right lateral and ventrodorsal views totaling 2 images available for review.

BREED

Domestic Short Hair

RADIOGRAPHIC FINDINGS

The degree of pulmonary inflation is deep.

The chest is mildly barrel shaped.

A moderate generalized bronchial lung pattern is noted and evenly distributed throughout the lung.

SEX

Female S

There is mild esophageal aerophagia.

Course and width of the trachea are within normal limits.

AGE

5-26-2010

The cardiac silhouette is upright and thin.

No evidence of mediastinal widening is noted.

INTERPRETED BY

Nele Eley, DVM
Dr. med. Vet. DipECVDI

The diaphragmatic cupola is mildly flat and the lumbodiaphragmatic angles are wide.

RADIOGRAPHIC DIAGNOSIS

- Bronchial lung pattern with air trapping.

HOSPITAL NAME

Cottage Grove
Veterinary Clinic

INTERPRETATION OF THE FINDINGS & FURTHER RECOMMENDATIONS

The radiographic findings are compatible with chronic lower airway disease with air trapping. Allergic lower airway syndrome is considered by far most likely, however, infectious bronchitis such as viral, bacterial, parasitic, or protozoal cannot be ruled out entirely. Consider further definition by means of airway sampling versus a clinical trial of treatment for feline asthma.

REFERRING VET

Damewood

INVOICE

51514

DATE

4-13-22



PATIENT

Abbie Owen

SPECIES

Feline

BREED

Domestic Short Hair

SEX

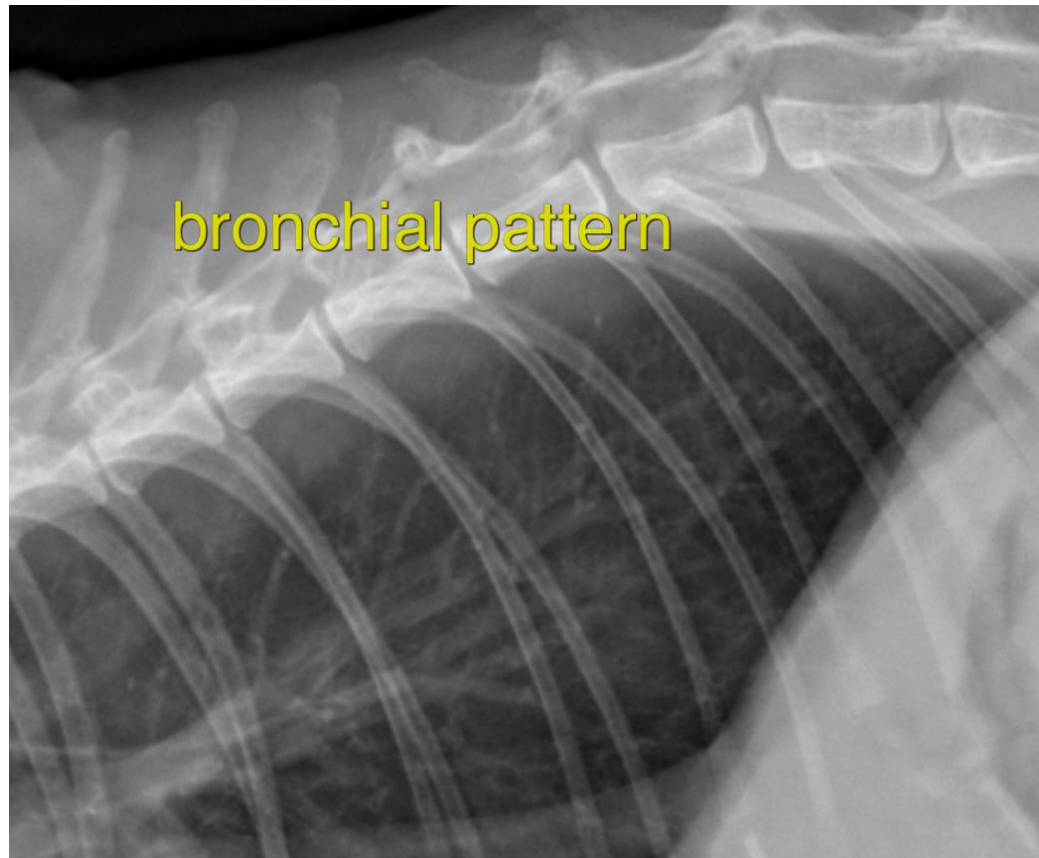
Female S

AGE

5-26-2010

INTERPRETED BY

Nele Eley, DVM
Dr. med. Vet. DipECVDI



HOSPITAL NAME

Cottage Grove
Veterinary Clinic

REFERRING VET

Damewood

INVOICE

51514

DATE

4-13-22

The information and recommendations provided are based on the images presented by the referring veterinarian/sonographer. No evaluation can be communicated regarding pathology that was not visible in the image/video clips provided.

Thank you for this referral. If the clinical or image interpretation does not parallel your findings or if I can be of any further assistance please contact me.

Nele Eley, DVM, Dr. med. vet., DipECVDI
European Specialist in Veterinary Diagnostic Imaging, Cert. Radiology,
Senior lecturer University of Giessen, Germany, Veterinary Faculty, Department of Radiology
Nele.Eley@sonopath.com