

**PATIENT**

Zach Flannery

**PRESENTING CLINICAL SIGNS**

Right nasal epistaxis

**SPECIES**

Canine

**COMPUTED TOMOGRAPHIC STUDY OF THE HEAD**

Post contrast study available for review.

**BREED**

Golden Retriever

**COMPUTED TOMOGRAPHIC FINDINGS**

Extensive turbinate destruction is seen within the right nasal cavity involving the rostral mid and caudal third of the nasal cavity. The remaining turbinates and general right nasal cavity present swelling of their mucosal lining. Calvarial hyperostosis is noted. Moderate mucosal proliferation with mineralization is noted within the right frontal sinus. The changes do not cross the midline. The left nasal cavity and left frontal sinus present within normal limits.

**SEX**

Male

Multifocal moderate to severe tooth root resorption is noted with no evidence of a dental-nasal fistula. There is no evidence of nasal foreign material. The cribriform plate is intact.

**AGE**

12 Years

Incidental otoliths are seen within both tympanic bullae. The conformation of both external auditory meatuses is narrow, yet they are patent at this point.

The right medial retropharyngeal lymph node presents mild symmetric enlargement.

**INTERPRETED BY**

Nele Eley, DVM  
Dr. med. Vet. DipECVDI

**COMPUTED TOMOGRAPHIC DIAGNOSIS**

- Unilateral right hand sided chronic destructive rhinosinusitis.
- Mild right medial retropharyngeal lymphadenomegaly.
- Multifocal tooth root resorption.

**HOSPITAL NAME**

Animal Surgical  
Center

**INTERPRETATION OF THE FINDINGS & FURTHER RECOMMENDATIONS**

The CT findings are highly suspicious for unilateral right hand sided aspergillosis. Other fungal rhinitis such as cryptococcus cannot be ruled out entirely. Bacterial or viral infection is highly unlikely based on the presence of extensive destructive changes. Further definition by means of rhinoscopy with sampling for culture including fungal culture is recommended if not performed already.

**REFERRING VET**

Tomas Infernuso

**INVOICE**

57769

**DATE**

4-12-23



**PATIENT**

Zach Flannery

**SPECIES**

Canine

**BREED**

Golden Retriever

**SEX**

Male

**AGE**

12 Years

**INTERPRETED BY**

Nele Eley, DVM  
Dr. med. Vet. DipECVDI

**HOSPITAL NAME**

Animal Surgical  
Center

**REFERRING VET**

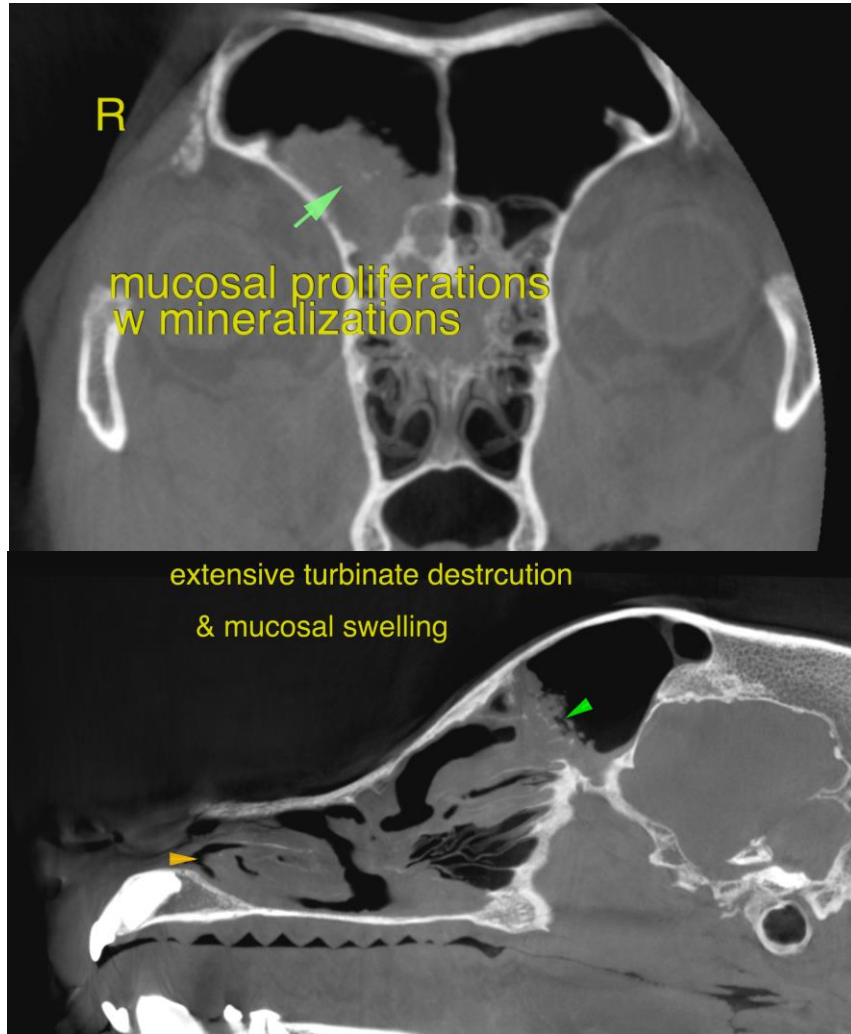
Tomas Infernuso

**INVOICE**

57769

**DATE**

4-12-23



The information and recommendations provided are based on the images presented by the referring veterinarian/sonographer. No evaluation can be communicated regarding pathology that was not visible in the image/video clips provided.

Thank you for this referral. If the clinical or image interpretation does not parallel your findings or if I can be of any further assistance please contact me.

**Nele Eley**, DVM, Dr. med. vet., DipECVDI  
European Specialist in Veterinary Diagnostic Imaging, Cert. Radiology,  
Senior lecturer University of Giessen, Germany, Veterinary Faculty, Department of Radiology  
Nele.Eley@sonopath.com