



PATIENT PRESENTING CLINICAL SIGNS

Silver Fernandez Owner reports pet showing signs of heat. Hx of OHE back in March 2022. Suspected ovarian remnant vs mass in the adrenal gland or other.
 Abnormal PE/Chem/CBC/UA Results: Antimullerian hormone test results inconclusive. HCT 31.9
 Chemistry: unremarkable

SPECIES

Feline

COMPUTED TOMOGRAPHIC STUDY OF THE ABDOMEN

Plain and post contrast studies available for review.

BREED

Siamese

COMPUTED TOMOGRAPHIC FINDINGS

The serosal fat presents normal attenuation behavior. There is no evidence of peritoneal effusion or peritonitis.

SEX

Spayed Female

An enlarged uterine stump is seen.

No evidence of residual tissue is seen in the position of the left ovary. There is a soft tissue attenuating perfused arrangement of tissue measuring approximately 14 x 4mm in the position of the right ovary which drains into the right ovarian vein.

AGE

3 Years

Both kidneys present within normal limits for size, shape and organ architecture. After contrast administration a bilaterally symmetric and uniform nephro- and pyelogram is noted.

INTERPRETED BY

Nele Eley (Ondreka),
 DVM Dr. med. vet.,
 DipECVDI

The adrenal glands are within normal limits for size, shape and organ architecture.

Both liver and spleen present with normal shape, even surface, uniformly attenuating parenchyma and homogeneous contrast enhancement, unremarkable.

The pancreas is evenly contoured, the pancreatic parenchyma is homogeneous and presents uniform contrast enhancement.

HOSPITAL NAME

Mobile Pet Imaging

The position, delineation, wall and content of the gastrointestinal tract are considered within normal limits throughout.

The bony and surrounding soft tissue structures reveal no abnormalities.

REFERRING VET

Meaux

COMPUTED TOMOGRAPHIC DIAGNOSIS

- Suspect right ovarian remnant.

INTERPRETATION OF FINDINGS & FURTHER RECOMMENDATIONS

INVOICE

57770

The CT findings do further support the tentative diagnosis of ovarian remnant. A 14 x 4mm sized structure is seen in the position of the right ovary that connects with the right ovarian vein and could well represent residual ovarian tissue.

DATE

4-12-23



PATIENT

Silver Fernandez

SPECIES

Feline

BREED

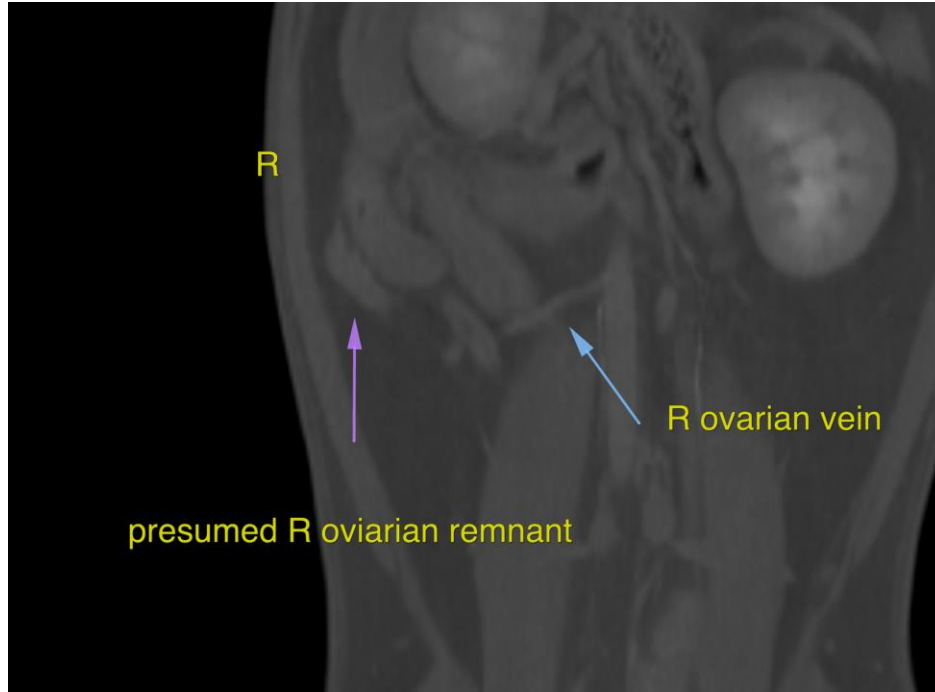
Siamese

SEX

Spayed Female

AGE

3 Years



INTERPRETED BY

Nele Eley (Ondreka),
DVM Dr. med. vet.,
DipECVDI

The information and recommendations provided are based on the images presented by the referring veterinarian. No evaluation can be communicated regarding pathology that was not visible in the image/video clips provided.

Thank you for this referral. If the clinical or image interpretation does not parallel your findings or if I can be of any further assistance please contact me.

HOSPITAL NAME

Mobile Pet Imaging

Nele Eley (Ondreka), DVM, Dr. med. vet., DipECVDI
European Specialist in Veterinary Diagnostic Imaging, Cert. Radiology,
Senior lecturer University of Giessen/Germany, Veterinary Faculty, Department of Radiology.
Nele.Eley@sonopath.com

REFERRING VET

Meaux

INVOICE

57770

DATE

4-12-23