



PATIENT

Diesel Mccauley

PRESENTING CLINICAL SIGNS

Hepatocellular carcinoma.

SPECIES

Canine

COMPUTED TOMOGRAPHIC STUDY OF THE THORAX & ABDOMEN

Plain and post contrast studies available for review. Streak artifacts interfere with the assessment of the thorax and cranial abdomen.

BREED

Labrador Mix

COMPUTED TOMOGRAPHIC FINDINGS

Abdomen

An approximately 4 x 6 cm sized irregular shaped and ill-defined heterogeneously enhancing mass is seen in the right division of the liver. No additional nodules or masses are recognized in the remainder of the liver. A small amount of mineral hyperattenuating material is present within the gallbladder.

SEX

Male

Occasional hyperenhancing splenic nodules are seen.

AGE

12 Years

The kidneys, adrenal glands, and pancreas present within age related normal limits.

Severe bilateral coxofemoral joint osteoarthritis secondary to canine hip dysplasia is seen.

There is moderate degenerative lumbosacral stenosis.

INTERPRETED BY

Nele Eley, DVM
Dr. med. Vet. DipECVDI

Thorax

No pulmonary nodules or masses are seen.

The mediastinal lymph nodes present within normal limits.

No overt evidence of cardiovascular pathology is noted.

HOSPITAL NAME

Animal Surgical
Center

COMPUTED TOMOGRAPHIC DIAGNOSIS

REFERRING VET

Dr. Impellizieri

- Large right divisional liver mass
- Splenic nodules
- Biliary microlithiasis
- Bilateral coxofemoral joint osteoarthritis secondary to severe canine hip dysplasia.
- Moderate degenerative lumbosacral stenosis.

INVOICE

57772

INTERPRETATION OF THE FINDINGS & FURTHER RECOMMENDATIONS

The CT study reveals presence of a large right divisional liver mass. Lobar origin from the right lateral liver lobe is considered most likely. However, caudate lobe involvement cannot be ruled out entirely. The mass is in a resectable position. No additional hepatic nodules are recognized.

DATE

4-12-23

The splenic nodules may represent extramedullary hematopoiesis, lymphoid hyperplasia, or metastases. Metastases is a lower potential but cannot be ruled out entirely.



PATIENT

Diesel Mccauley

SPECIES

Canine

BREED

Labrador Mix

SEX

Male

AGE

12 Years

INTERPRETED BY

Nele Eley, DVM
Dr. med. Vet. DipECVDI

HOSPITAL NAME

Animal Surgical
Center

REFERRING VET

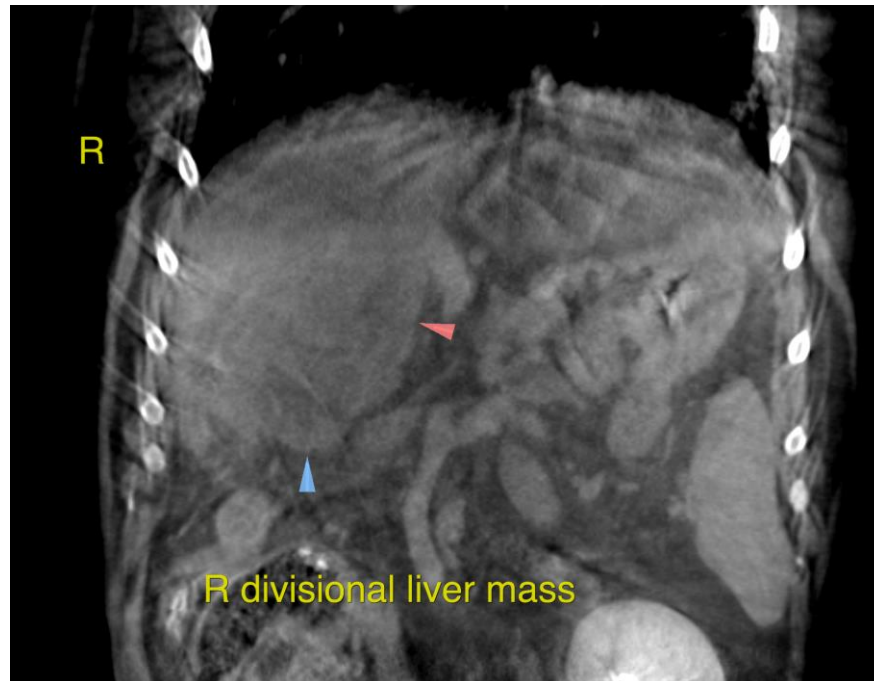
Dr. Impellizieri

INVOICE

57772

DATE

4-12-23



The information and recommendations provided are based on the images presented by the referring veterinarian/sonographer. No evaluation can be communicated regarding pathology that was not visible in the image/video clips provided.

Thank you for this referral. If the clinical or image interpretation does not parallel your findings or if I can be of any further assistance please contact me.

Nele Eley, DVM, Dr. med. vet., DipECVDI
European Specialist in Veterinary Diagnostic Imaging, Cert. Radiology,
Senior lecturer University of Giessen, Germany, Veterinary Faculty, Department of Radiology
Nele.Eley@sonopath.com