

**PATIENT**

Tigger Thorner

PRESENTING CLINICAL SIGNS

Pet has chronic stomatitis. Most recent dental at rDVM was in Feb. Owner thinks pet is still painful. Paws at his head and neck, and yowls as if he is in pain. rDVM gave a DepoMedrol injection last week- unsure if it helped. Chem 17/ CBC/Lytes at rDVM were NSF. Owner is concerned that something other than the stomatitis is causing him pain.

SPECIES

Feline

COMPUTED TOMOGRAPHIC STUDY OF THE HEAD

Plain and post contrast studies available for review.

BREED

DSH

COMPUTED TOMOGRAPHIC FINDINGS

Tooth root remnants of the mesial and distal root of the triadan 307 are seen. The remainder of the tooth roots present within normal age related limits. No significant periodontal changes are noted.

SEX

MN

The temporomandibular joints present within normal limits.

AGE

5 Years, 10 Months

Small areas of turbinate destruction with regional mucosal swelling are seen within the right nasal cavity. Both frontal sinuses and the left nasal cavity present within normal limits.

Mild nasopharyngeal fluid accumulation is noted.

The tympanic bullae and ear canals present within normal limits.

Minimal right sided submandibular and medial retropharyngeal lymphadenomegaly is noted.

INTERPRETED BY

Nele Eley, DVM
Dr. med. Vet. DipECVDI

COMPUTED TOMOGRAPHIC DIAGNOSIS

- Tooth root remnants triadan 307- not necessarily of clinical significance, clinical correlation required.
- Mild destructive rhinitis - right nasal cavity.
- Minimal right medial retropharyngeal and submandibular lymphadenomegaly.

HOSPITAL NAME

Wilson Veterinary
Hospital

INTERPRETATION OF THE FINDINGS & FURTHER RECOMMENDATIONS**REFERRING VET**

Dr. John Wilson

Differential diagnosis for the nasal changes includes early lymphoplasmacytic or infectious rhinitis such as viral or bacterial. Consider further definition by means of airway sampling with endoscopy if available. The changes are mild at this point, yet they may progress.

The lymph node changes are compatible with reactive lymphadenitis.

INVOICE

51489

DATE

4-12-22



PATIENT

Tigger Thorner

SPECIES

Feline

BREED

DSH

SEX

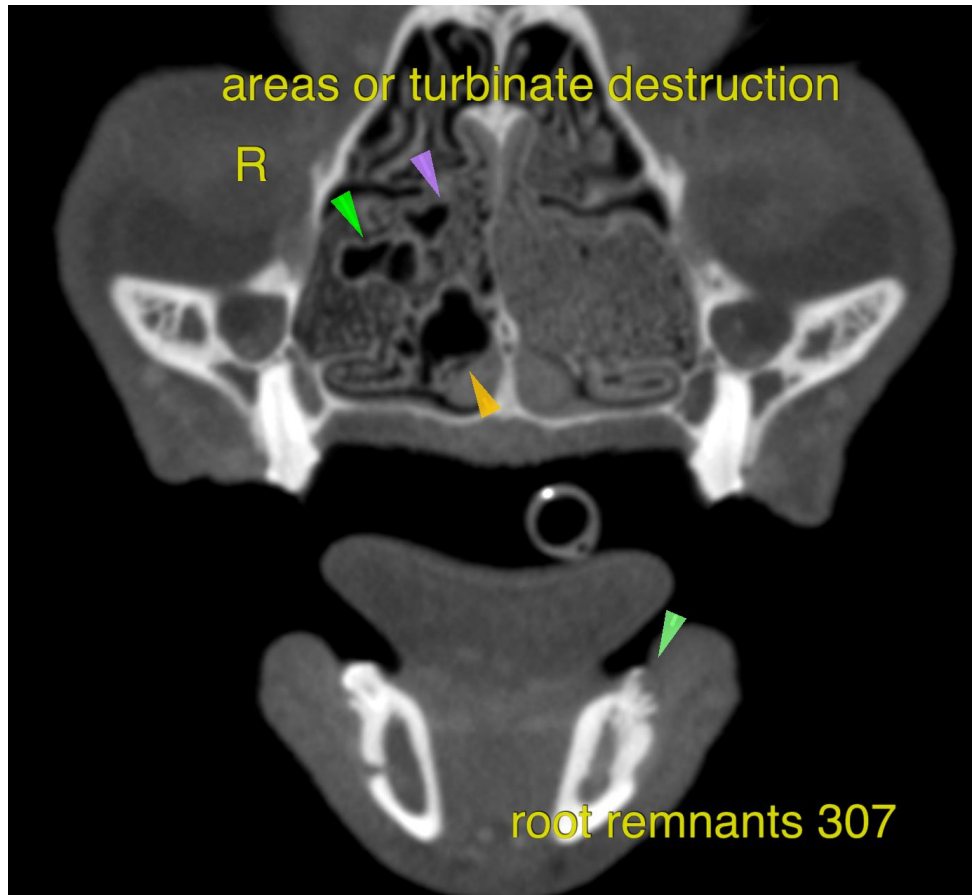
MN

AGE

5 Years, 10 Months

INTERPRETED BY

Nele Eley, DVM
Dr. med. Vet. DipECVDI



HOSPITAL NAME

Wilson Veterinary
Hospital

REFERRING VET

Dr. John Wilson

INVOICE

51489

DATE

4-12-22

The information and recommendations provided are based on the images presented by the referring veterinarian/sonographer. No evaluation can be communicated regarding pathology that was not visible in the image/video clips provided.

Thank you for this referral. If the clinical or image interpretation does not parallel your findings or if I can be of any further assistance please contact me.

Nele Eley, DVM, Dr. med. vet., DipECVDI
European Specialist in Veterinary Diagnostic Imaging, Cert. Radiology,
Senior lecturer University of Giessen, Germany, Veterinary Faculty, Department of Radiology
Nele.Eley@sonopath.com