



PATIENT PRESENTING CLINICAL SIGNS

PATIENT Fluffy Serrano
PRESENTING CLINICAL SIGNS Owner rolled over onto pet while sleeping, screaming in pain has been on methadone and gabapentin, no relief, reluctant to move around

SPECIES RADIOGRAPHIC STUDY OF THE CERVICAL, THORACIC, & LUMBAR SPINE

SPECIES Canine
 The craniocervical junction presents within normal limits. No evidence of abnormality of the odontoid peg or atlantoaxial instability is seen.

BREED Maltese
 Number, alignment, and general anatomy of the cervical vertebrae present within normal limits.

SEX Female/sp
 Number, alignment, and general anatomy of the thoracolumbar vertebrae are considered within normal limits as well.

Mineralized intervertebral disc material is superimposed onto the neuroforamina L6/7 and L7/S1. The L7/S1 in situ disc is mineralized as well.

No evidence of traumatic osseous injury can be seen.

AGE RADIOGRAPHIC DIAGNOSIS

- AGE** 5 Years
- Normal radiographic presentation of the cervical and thoracic spine.
 - Lumbosacral stenosis with presumed mineralized intervertebral disc extrusion L6/7 and chondroid disc degeneration L7/S1.

INTERPRETED BY

Nele Eley, DVM
 Dr. med. Vet. DipECVDI

INTERPRETATION OF THE FINDINGS & FURTHER RECOMMENDATIONS

An overt underlying cause of the cervical signs / pain cannot be identified radiographically. The radiographic presentation of the cervical spine and craniocervical junction is within normal limits which does not necessarily rule out disc hernia or other myelopathy. Further definition by means of cross sectional imaging could be considered should the patient's clinical signs persist or deteriorate.

HOSPITAL NAME

New Bridge
 Veterinary Practice

The findings in the lumbosacral region suggest potential for lumbosacral stenosis which, however, may not be significant in the context of the current clinical presentation.

REFERRING VET

Dr. Abina Glennon

INVOICE

51474

DATE

4-12-22



PATIENT

Fluffy Serrano

SPECIES

Canine

BREED

Maltese

SEX

Female/sp

AGE

5 Years

INTERPRETED BY

Nele Eley, DVM
Dr. med. Vet. DipECVDI

HOSPITAL NAME

New Bridge
Veterinary Practice

REFERRING VET

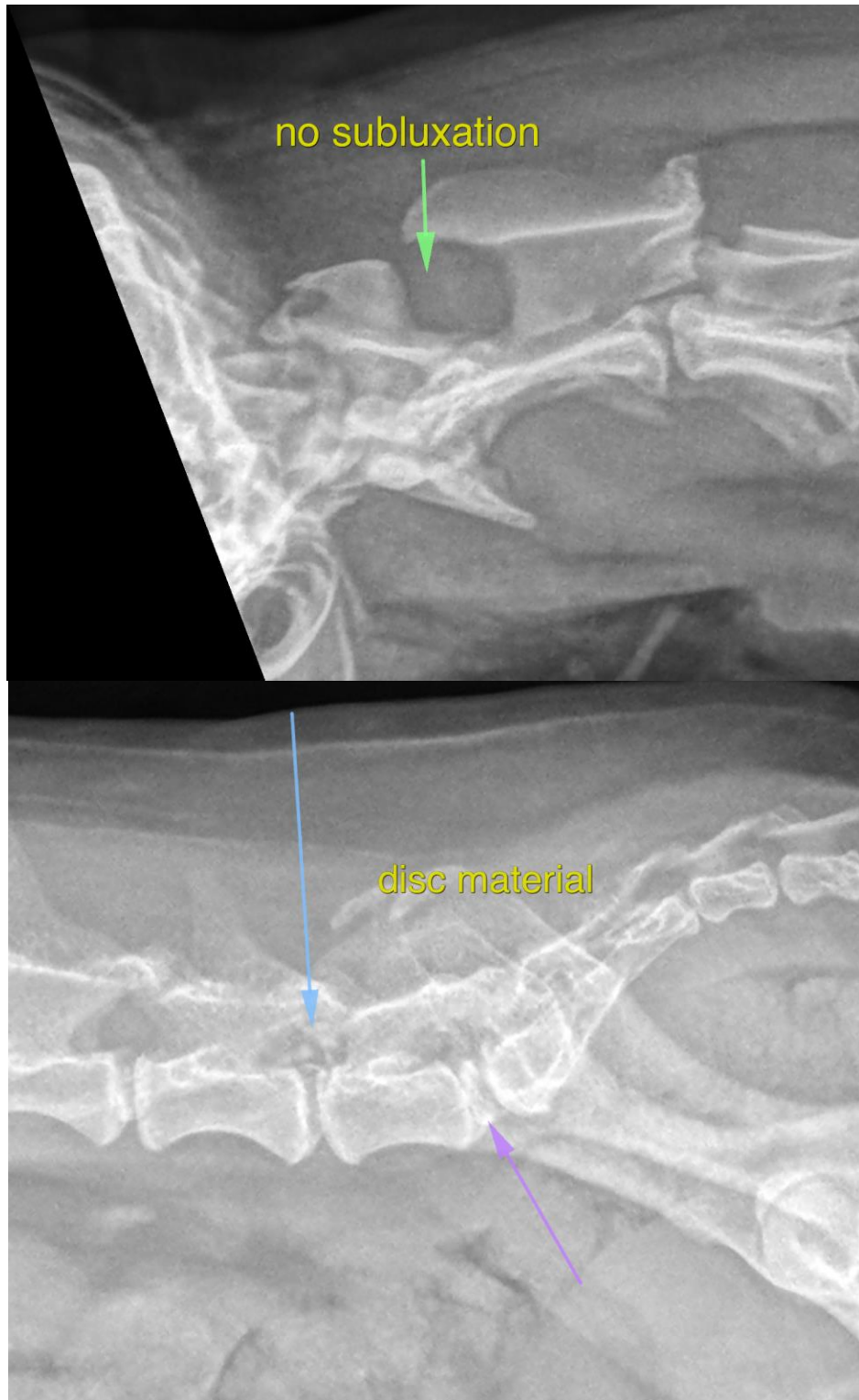
Dr. Abina Glennon

INVOICE

51474

DATE

4-12-22





PATIENT

Fluffy Serrano

The information and recommendations provided are based on the images presented by the referring veterinarian/sonographer. No evaluation can be communicated regarding pathology that was not visible in the image/video clips provided.

SPECIES

Canine

Thank you for this referral. If the clinical or image interpretation does not parallel your findings or if I can be of any further assistance please contact me.

BREED

Maltese

Nele Eley, DVM, Dr. med. vet., DipECVDI
European Specialist in Veterinary Diagnostic Imaging, Cert. Radiology,
Senior lecturer University of Giessen, Germany, Veterinary Faculty, Department of Radiology
Nele.Eley@sonopath.com

SEX

Female/sp

AGE

5 Years

INTERPRETED BY

Nele Eley, DVM
Dr. med. Vet. DipECVDI

HOSPITAL NAME

New Bridge
Veterinary Practice

REFERRING VET

Dr. Abina Glennon

INVOICE

51474

DATE

4-12-22