

PATIENT PRESENTING CLINICAL SIGNS

Luna Hishon Left sided epistaxis for 1 day duration
Abnormal PE/Chem/CBC/UA Results: ALT 156, all else WNL, Coags normal

SPECIES COMPUTED TOMOGRAPHIC STUDY OF THE NASAL CAVITY

Canine Plain and post contrast studies are available for review.

COMPUTED TOMOGRAPHIC FINDINGS

BREED
Pit Mix Bilateral polypoid mucosal proliferations are present within the frontal sinuses. The left frontal sinus additionally shows partial to complete fluid attenuation. Mild left side fluid accumulation is seen in the maxillary sinus.

SEX Fluid accumulations and mucosal swelling are noted within the left nasal cavity. There is no evidence of turbinate destruction or mass lesion.

FS No foreign material is identified.

AGE There is no significant structural nasal cavity asymmetry.

11yr No relevant dental pathology can be identified that would explain the current clinical signs.

No aggressive bone lysis or remodeling is detected.

INTERPRETED BY

Nele Eley (Ondreka),
DVM Dr. med. vet.,
DipECVDI

COMPUTED TOMOGRAPHIC DIAGNOSIS

- Bilateral chronic frontal sinusitis
- Left sided sinus and nasal cavity effusion
- No imaging evidence of nasal neoplasia, destructive rhinitis or foreign body related disease

HOSPITAL NAME

Wilson Veterinary
Hospital

INTERPRETATION OF FINDINGS & FURTHER RECOMMENDATIONS

The findings are most consistent with chronic inflammatory or infectious polypoid sinus disease. The changes appear to be chronic in nature despite the acute onset of epistaxis. The absence of turbinate destruction, mass lesion or bone lysis makes aggressive neoplasia or longstanding invasive fungal disease unlikely. Infectious and/ or inflammatory causes appear to be a primary underlying cause of the CT changes and unilateral epistaxis.

REFERRING VET

Nicholas Vitale, DVM

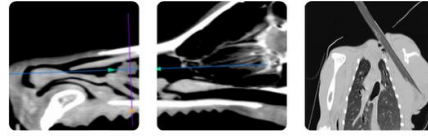
Consider rhinoscopy with sampling for biopsy and culture if clinical signs persist or for further definition.

INVOICE

24475

DATE

04/11/2026



PATIENT

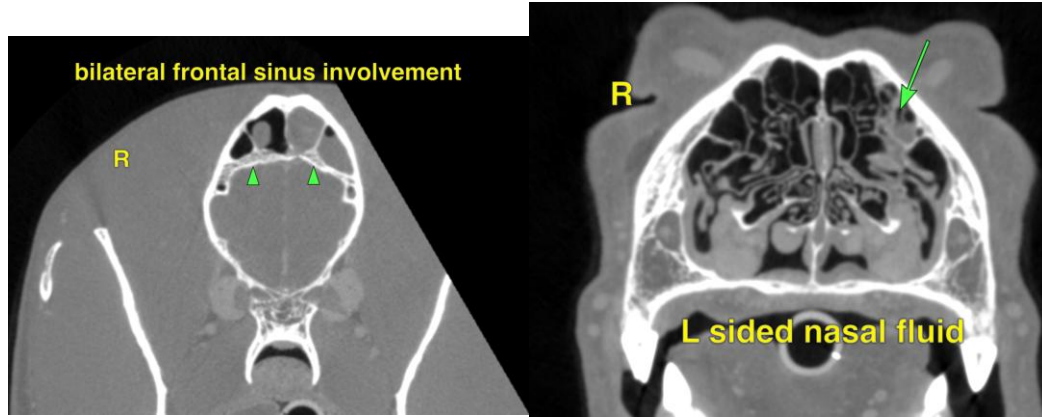
Luna Hishon

SPECIES

Canine

BREED

Pit Mix



SEX

FS

AGE

11yr

INTERPRETED BY

Nele Eley (Ondreka),
DVM Dr. med. vet.,
DipECVDI

HOSPITAL NAME

Wilson Veterinary
Hospital

REFERRING VET

Nicholas Vitale, DVM

INVOICE

24475

DATE

04/11/2026

The information and recommendations provided are based on the images presented by the referring veterinarian. No evaluation can be communicated regarding pathology that was not visible in the image/video clips provided.

Thank you for this referral. If the clinical or image interpretation does not parallel your findings or if I can be of any further assistance please contact me.

Nele Eley (Ondreka), DVM, Dr. med. vet., DipECVDI
European Specialist in Veterinary Diagnostic Imaging, Cert. Radiology,
Senior lecturer University of Giessen/Germany, Veterinary Faculty, Department of Radiology.
info@sonopath.com