



PATIENT

Tonka Crickenberger

PRESENTING CLINICAL SIGNS

Lameness more evident at walk than trot. Crosses rear legs when walking and decreased weight bearing on right rear. Muscle atrophy caudal thigh muscles. Wide based stance in front limbs with apparent increased weight bearing.

SPECIES

Canine

ULTRASONOGRAPHIC FINDINGS

Left Stifle

BREED

Pit Mix

Mild effusion is seen within the left stifle joint. The lateral and medial menisci are in situ, smoothly delineated, and present uniform internal echoarchitecture. The patella tendon and infrapatellar fat present within normal limits.

SEX

Neutered Male

The cranial cruciate ligament is not directly seen. No evidence of abnormality is seen in the region superficial to the cranial cruciate ligament.

Right Stifle

Mild effusion is noted within the right stifle joint.

AGE

11 Months

Part of the cranial cruciate ligament is seen in the far field and presents within normal limits.

The medial and lateral meniscus are in situ, smoothly delineated, and present uniform internal echoarchitecture.

INTERPRETED BY

Nele Eley, DVM
Dr. med. Vet. DipECVDI

ULTRASONOGRAPHIC DIAGNOSIS

- Mild bilateral stifle effusion.
- No evidence of meniscopathy.
- No evidence of cruciate ligament injury.

HOSPITAL NAME

County Line
Veterinary Clinic

INTERPRETATION OF THE FINDINGS & FURTHER RECOMMENDATIONS

The assessment of the left cranial cruciate ligament is limited. Injury of the cruciate ligament is however not directly seen, and the lateral and medial meniscus present within normal limits.

REFERRING VET

Elizabeth Fowler

Part of the right cranial cruciate ligament is cut off in the far field however the presentation of the right cranial cruciate ligament is within normal limits as far as seen.

Other causes of arthropathy including immune mediated arthritis, overload, trauma are potential considerations. Further clinical monitoring with eventual ultrasonographic recheck could be considered.

INVOICE

57751

DATE

4-11-23



PATIENT

Tonka Crickenberger

SPECIES

Canine

BREED

Pit Mix

SEX

Neutered Male

AGE

11 Months

INTERPRETED BY

Nele Eley, DVM
Dr. med. Vet. DipECVDI

HOSPITAL NAME

County Line
Veterinary Clinic

REFERRING VET

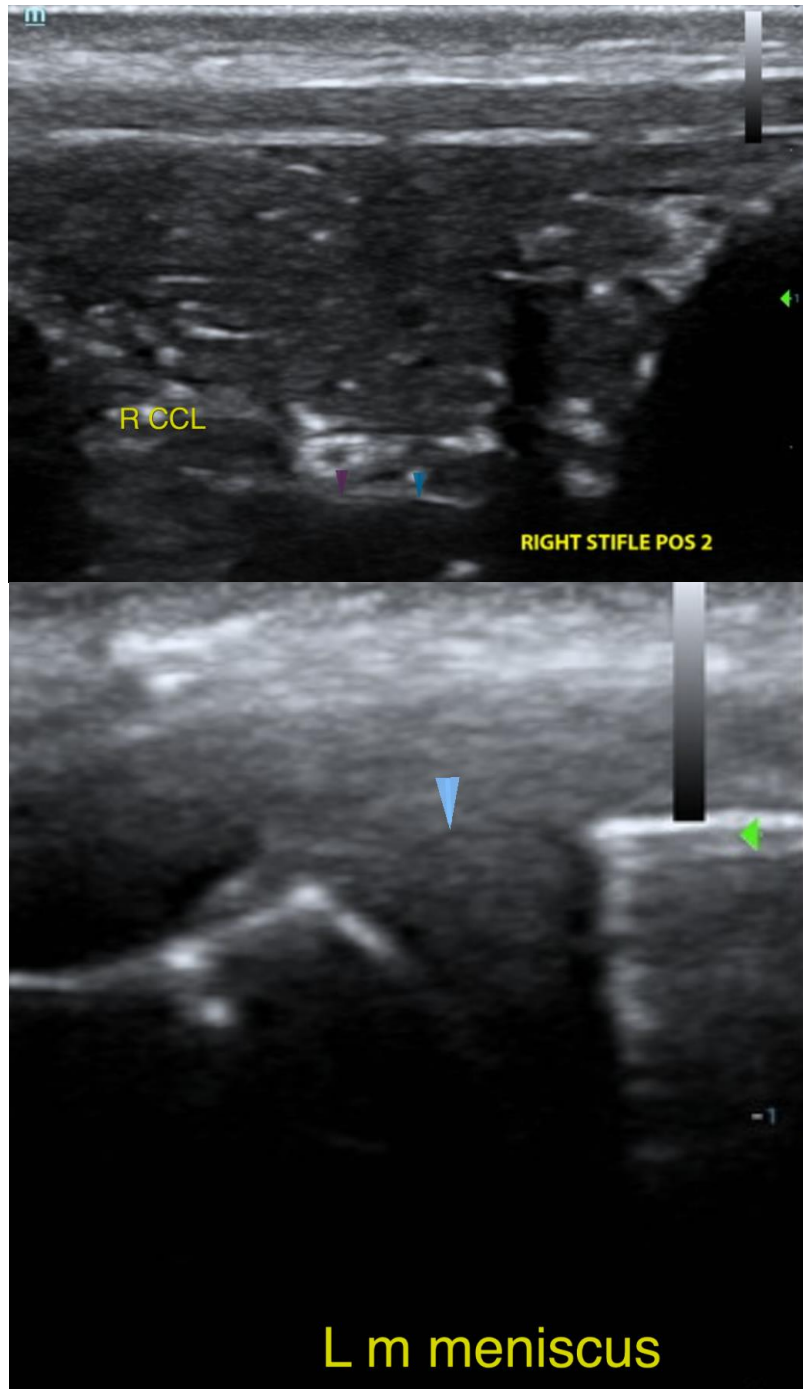
Elizabeth Fowler

INVOICE

57751

DATE

4-11-23





PATIENT

Tonka Crickenberger

The information and recommendations provided are based on the images presented by the referring veterinarian/sonographer. No evaluation can be communicated regarding pathology that was not visible in the image/video clips provided.

SPECIES

Canine

Thank you for this referral. If the clinical or image interpretation does not parallel your findings or if I can be of any further assistance please contact me.

BREED

Pit Mix

Nele Eley, DVM, Dr. med. vet., DipECVDI
European Specialist in Veterinary Diagnostic Imaging, Cert. Radiology,
Senior lecturer University of Giessen, Germany, Veterinary Faculty, Department of Radiology
Nele.Eley@sonopath.com

SEX

Neutered Male

AGE

11 Months

INTERPRETED BY

Nele Eley, DVM
Dr. med. Vet. DipECVDI

HOSPITAL NAME

County Line
Veterinary Clinic

REFERRING VET

Elizabeth Fowler

INVOICE

57751

DATE

4-11-23