



PATIENT

Marilyn Monroe
Perkins

PRESENTING CLINICAL SIGNS

Right forelimb lameness several weeks. O has been trying to rest her and it's not improving. Abnormal PE/Chem/CBC/UA Results: pain on R carpal flexion, abducting both elbows R>L. O reports reactive to extension but unable to do during awake exam, no response during sedation. grade 1 left pulmonic systolic ejection murmur

SPECIES

Canine

RADIOGRAPHIC STUDY OF THE CARPI & ELBOWS

Neutral mediolateral, and flexed mediolateral, as well as craniocaudal views of the right carpus, neutral mediolateral and craniocaudal views of the left carpus, mediolateral and craniocaudal views of elbows totaling 6 images available for review.

BREED

Pit Bull X

RADIOGRAPHIC FINDINGS

Elbows

SEX

SF

The medial coronoid processes are uniformly opacified and smoothly delineated in both elbows. The joint spaces are congruent. No evidence of subchondral bone defects is seen.

A small osteophyte is seen proximally on the anconeus process in the right elbow.

AGE

5 Years

No evidence of significant osteophytosis is noted in the left elbow.

Carp

INTERPRETED BY

Nele Eley, DVM
Dr. med. Vet. DipECVDI

No significant soft tissue swelling, and no evidence of osseous injury is seen in the left and right carpus. The subchondral bone surfaces are intact and smooth. There is no evidence of degenerative joint disease.

The metacarpophalangeal joints present within normal limits in both front limbs.

HOSPITAL NAME

Northshore
Veterinary Hospital

Note the presence of periarticular osteophytes and greater humeral tubercle enthesophytosis in the right shoulder.

RADIOGRAPHIC DIAGNOSIS

REFERRING VET

Dr. Sophie Lee

- Mild degenerative joint disease of the right elbow.
- Normal radiographic presentation of the carpi.
- Right shoulder osteoarthritis and evidence of supraspinatus tendinopathy.

INTERPRETATION OF THE FINDINGS & FURTHER RECOMMENDATIONS

INVOICE

57750

Mild osteoarthritis of the right elbow is noted with no evidence of underlying medial coronoid pathology or osteochondritis. Clinical significance is uncertain.

Note the presence of moderate right shoulder osteoarthritis with evidence of supraspinatus tendinopathy. Clinical correlation is required.

DATE

4-11-23

The radiographic presentation of the carpal joints was within normal limits.



PATIENT

Marilyn Monroe
Perkins

SPECIES

Canine

BREED

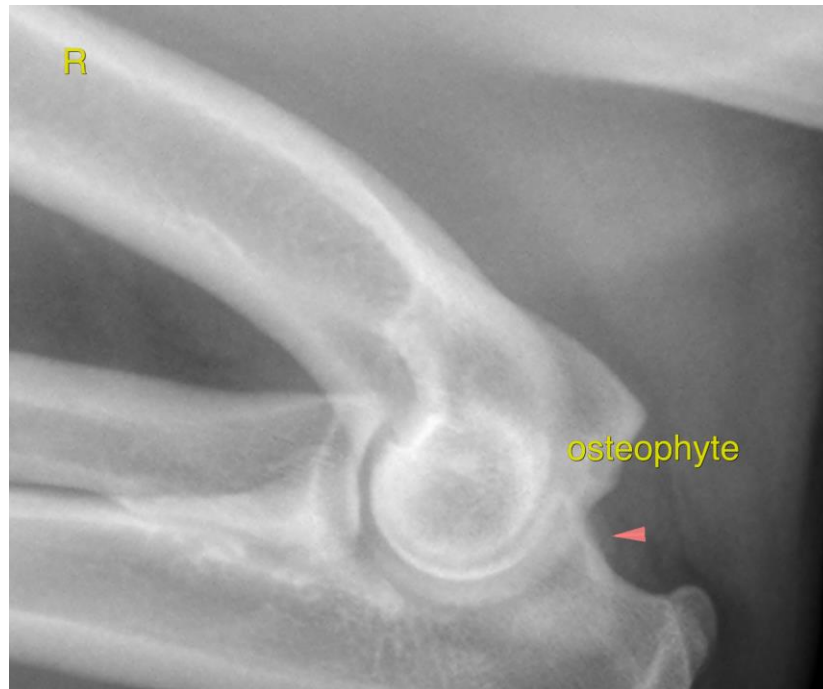
Pit Bull X

SEX

SF

AGE

5 Years



INTERPRETED BY

Nele Eley, DVM
Dr. med. Vet. DipECVDI

The information and recommendations provided are based on the images presented by the referring veterinarian/sonographer. No evaluation can be communicated regarding pathology that was not visible in the image/video clips provided.

Thank you for this referral. If the clinical or image interpretation does not parallel your findings or if I can be of any further assistance please contact me.

HOSPITAL NAME

Northshore
Veterinary Hospital

Nele Eley, DVM, Dr. med. vet., DipECVDI
European Specialist in Veterinary Diagnostic Imaging, Cert. Radiology,
Senior lecturer University of Giessen, Germany, Veterinary Faculty, Department of Radiology
Nele.Eley@sonopath.com

REFERRING VET

Dr. Sophie Lee

INVOICE

57750

DATE

4-11-23