



PATIENT

Sweet Pea Munir

PRESENTING CLINICAL SIGNS

Sweet Pea came in today as she had no bowel movement for 4 days, eating less and lethargic . no vomiting / sneezing or coughing . no food or environmental changes

SPECIES

Feline

RADIOGRAPHIC STUDY OF THE ABDOMEN

Right/left lateral and ventrodorsal views totaling 3 images available for review.

BREED

British Short Hair

RADIOGRAPHIC FINDINGS

Subinguinal lymphadenomegaly is noted and compatible with juvenile hyperplasia.

SEX

F

The abdominal serosal detail is maintained.

The spleen is relatively prominent.

AGE

5 Months

The stomach contains a moderate amount of granulated material compatible with ingesta. Time of last meal should be double checked.

The small intestinal loops are evenly distributed throughout the mid abdomen. No evidence of abnormal dilation, plication, or radiopaque foreign material is seen.

INTERPRETED BY

Nele Eley, DVM
Dr. med. Vet. DipECVDI

The colon contains a mild amount of fecal matter only. No evidence of constipation, dilation, or stenosis is seen.

The patient has a lumbosacral transitional vertebra.

HOSPITAL NAME

Brittany Glen Animal
Hospital

RADIOGRAPHIC DIAGNOSIS

- Mild splenomegaly.
- Mild lymphadenomegaly.
- Post-prandial stomach.
- No evidence of mechanical small intestinal ileus.
- Largely empty colon.

REFERRING VET

Dr. Boktor

INTERPRETATION OF THE FINDINGS & FURTHER RECOMMENDATIONS

The radiographic study reveals no signs of mechanical small intestinal ileus. No foreign material and no plication is seen. Please double check timing of last meal since the stomach appears to contain a moderate amount of ingesta with relatively solid appearance.

INVOICE

51442

The mild splenomegaly and lymphadenomegaly is considered compatible with juvenile hyperplasia. Splenitis, reactive hyperplasia owing to systemic disease, and infiltrative pathology all are thought unlikely.

DATE

4-11-22



PATIENT

Sweet Pea Munir

SPECIES

Feline

BREED

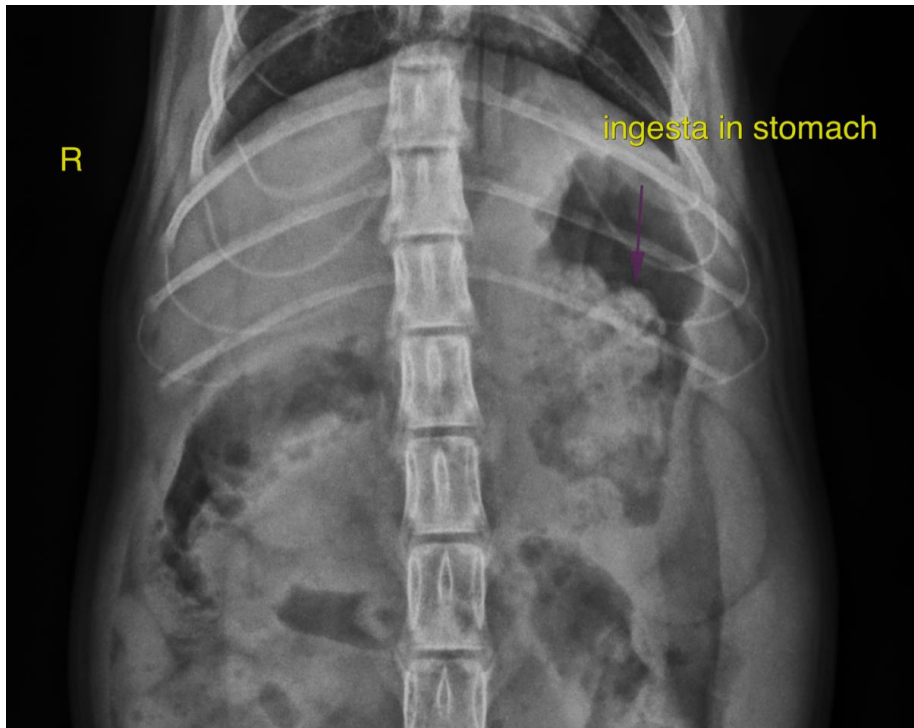
British Short Hair

SEX

F

AGE

5 Months



INTERPRETED BY

Nele Eley, DVM
Dr. med. Vet. DipECVDI

The information and recommendations provided are based on the images presented by the referring veterinarian/sonographer. No evaluation can be communicated regarding pathology that was not visible in the image/video clips provided.

HOSPITAL NAME

Brittany Glen Animal
Hospital

Thank you for this referral. If the clinical or image interpretation does not parallel your findings or if I can be of any further assistance please contact me.

Nele Eley, DVM, Dr. med. vet., DipECVDI
European Specialist in Veterinary Diagnostic Imaging, Cert. Radiology,
Senior lecturer University of Giessen, Germany, Veterinary Faculty, Department of Radiology
Nele.Eley@sonopath.com

REFERRING VET

Dr. Boktor

INVOICE

51442

DATE

4-11-22