



**PATIENT**

Misha Parham

**PRESENTING CLINICAL SIGNS**

Pt presents with dry non productive cough that started about 3 months ago. Occurs about 4 times a day per Owner. Pt also has history of oral squamous cell carcinoma. Sent out desert blood profile, VF test came back negative.

**SPECIES**

Canine

**RADIOGRAPHIC STUDY OF THE THORAX**

Right/left lateral and ventrodorsal views totaling 7 images available for review.

**BREED**

Great Pyrenees

**RADIOGRAPHIC FINDINGS**

The degree of pulmonary inflation is moderate.

**SEX**

Spayed Female

A moderate generalized bronchial lung pattern with multifocal peribronchial cuffing is noted and evenly distributed throughout the lung. Occasional age related pulmonary osteomas are noted as well and considered incidental. No evidence of interstitial pulmonary nodules or masses is noted.

Course and width of the trachea are within normal limits.

**AGE**

9 Years, 5 Months

The cardiac silhouette presents within normal limits. There is no evidence of specific chamber enlargement or generalized enlargement. The vertebral heart score is 10.

There is no evidence of mediastinal lymphadenomegaly.

**INTERPRETED BY**

Nele Eley, DVM  
Dr. med. Vet. DipECVDI

No evidence of upper or lower airway collapse is seen.

**RADIOGRAPHIC DIAGNOSIS**

- No evidence of interstitial pulmonary nodules/metastatic disease.
- Moderate bronchial lung pattern.

**HOSPITAL NAME**

Ahwatukee Commons  
Veterinary Hospital

**INTERPRETATION OF THE FINDINGS & FURTHER RECOMMENDATIONS**

The radiographic study reveals a chronic lower airway pattern. Consider eosinophilic / allergic bronchopneumopathy versus infectious bronchitis such as viral, bacterial, parasitic, and less likely protozoal. Airway endoscopy with airway sampling would be ideal for further definition in this patient.

**REFERRING VET**

Dr. Rebecca R.  
Housley

**INVOICE**

51452

**DATE**

4-11-22



**PATIENT**

Misha Parham

**SPECIES**

Canine

**BREED**

Great Pyrenees

**SEX**

Spayed Female

**AGE**

9 Years, 5 Months

**INTERPRETED BY**

Nele Eley, DVM  
Dr. med. Vet. DipECVDI

**HOSPITAL NAME**

Ahwatukee Commons  
Veterinary Hospital

**REFERRING VET**

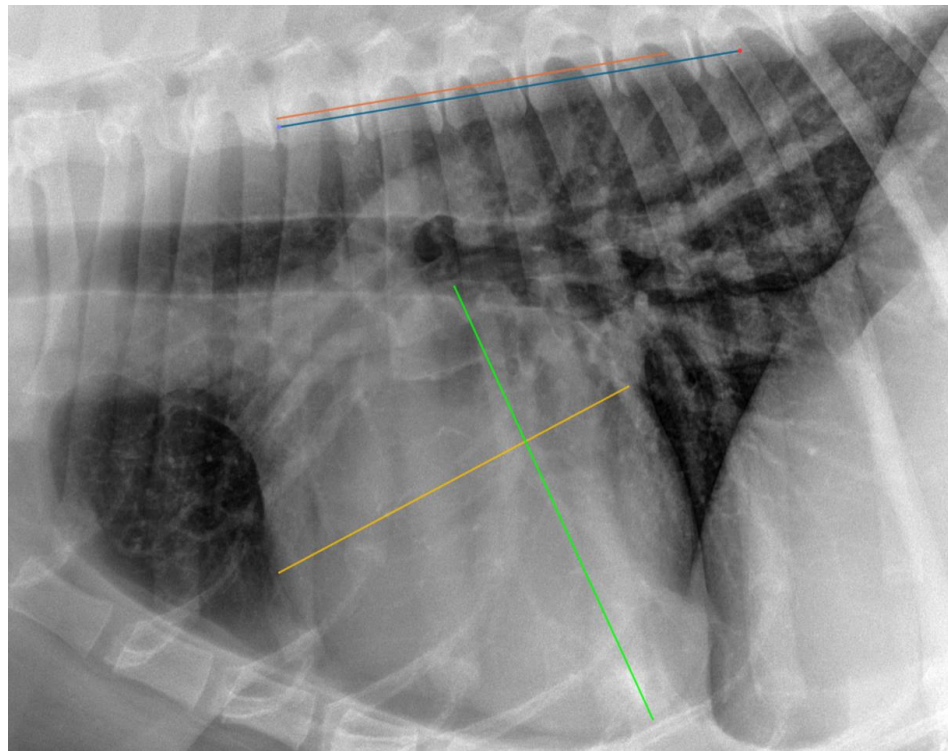
Dr. Rebecca R.  
Housley

**INVOICE**

51452

**DATE**

4-11-22



**The information and recommendations provided are based on the images presented by the referring veterinarian/sonographer. No evaluation can be communicated regarding pathology that was not visible in the image/video clips provided.**

Thank you for this referral. If the clinical or image interpretation does not parallel your findings or if I can be of further assistance please contact me.

**Nele Eley, DVM, Dr. med. vet., DipECVDI**  
European Specialist in Veterinary Diagnostic Imaging, Cert. Radiology,  
Senior lecturer University of Giessen, Germany, Veterinary Faculty, Department of Radiology  
Nele.Eley@sonopath.com